



# Do Not Take for Granted! The Art of Elevating the Capsule in Hip Arthroscopy: A Stepwise Approach

David R. Maldonado, M.D., Jeffrey W. Chen, B.A., Ajay C. Lall, MD, M.S., Cynthia Kyin, B.A., Rafael Walker-Santiago, M.D., Philip J. Rosinsky, M.D., Jacob Shapira, M.D., and Benjamin G. Domb, M.D.

**Abstract:** Different techniques have been described to close or plicate the capsule. To perform these procedures, however, the capsule must be preserved, a consideration unfortunately often overlooked. This Technical Note describes in a stepwise manner the initial capsular management necessary to preserve the capsule for further procedures such as closure or plication. Level of Evidence: I (hip), II (impingement, labrum, other).

**H**ip arthroscopy has been shown to result in favorable outcomes in the treatment of specific hip pathologies such as labral tears and femoroacetabular impingement.<sup>1-4</sup> Biomechanical evidence strongly supports the role of capsular repair in maintaining stability of the hip.<sup>5-7</sup> It has been suggested that capsular closure after hip arthroscopy may reduce instability of the joint and reduce revision

rates, especially in patients with ligamentous laxity or borderline dysplasia. Regarding outcomes, a recent systematic review concluded that capsular closure is safe and effective in nonarthritic patients undergoing hip arthroscopic procedures and yields outcomes superior to unrepaired capsulotomies at short-term follow-up.<sup>6</sup> This Technical Note presents our preferred way to elevate the capsule in a reproducible manner (Table 1).

From the American Hip Institute, Des Plaines, Illinois, U.S.A.

The authors report the following potential conflicts of interest or sources of funding: A.C.L. reports grants and nonfinancial support from Arthrex, nonfinancial support from Iroko, Medwest, Smith & Nephew, Stryker, Vericel, Zimmer Biomet. B.G.D. reports grants from Arthrex, Medacta, Stryker, grants and other from American Orthopedic Foundation; personal fees from Adventist Hinsdale Hospital, Orthomerica; personal fees and nonfinancial support from Amplitude; grants, personal fees, and nonfinancial support from Arthrex, Pacira Pharmaceuticals, Stryker; personal fees from DJO Global; grants from Kaufman Foundation; grants and personal fees from Medacta; grants from Breg. In addition, B.G.D. has a patent 8920497 with royalties paid to Arthrex, a patent 8708941 with royalties paid to Orthomerica and DJO Global, and a patent 9737292 with royalties paid to Arthrex. B.G.D. is a board member for the American Orthopedic Foundation, American Hip Foundation, Arthroscopy Editorial Board, AANA Learning Center Committee, Hinsdale Hospital Foundation, and has ownership interests in Hinsdale Orthopedic Associates, Hinsdale Orthopedic Imaging, American Hip Institute, SCD#3, North Shore Surgical Suites, Munster Specialty Surgery Center. Full ICMJE author disclosure forms are available for this article online, as supplementary material.

Received February 23, 2019; accepted April 2, 2019.

Address correspondence to Benjamin G. Domb, M.D., American Hip Institute, 999 E Touhy Ave, Suite 450, Des Plaines, IL 60018, U.S.A. E-mail: [DrDomb@americanhipinstitute.org](mailto:DrDomb@americanhipinstitute.org)

© 2019 by the Arthroscopy Association of North America. Published by Elsevier. This is an open access article under the CC BY-NC-ND license (<http://creativecommons.org/licenses/by-nc-nd/4.0/>).

2212-6287/19232

<https://doi.org/10.1016/j.eats.2019.04.003>

## Surgical Technique

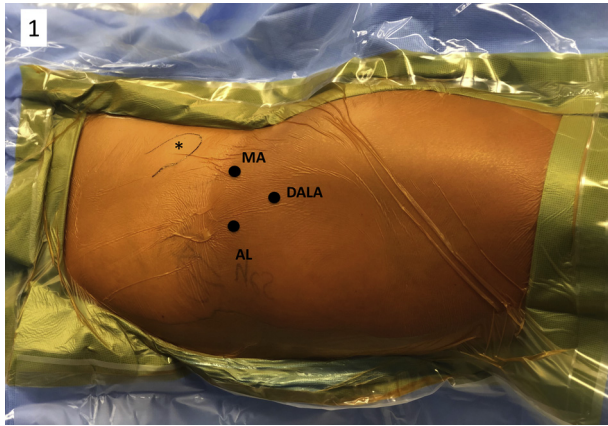
### Patient Preparation and Positioning

General anesthesia is administered to achieve skeletal relaxation. The patient is placed in the modified supine position on a traction table with an extra-padded post. Special care is taken to provide extra padding to the feet as well.

**Table 1.** Pearls and Pitfalls

Pearls	Pitfalls
<ul style="list-style-type: none"><li>Working through the DALA portal offers a better “attack angle” for elevating the capsule.</li><li>When using the RF device to perform the initial elevation, start 2 to 3 mm away from the capsule.</li><li>At the beginning of the learning curve, a less aggressive setting such as “coagulation mode” can be used on the RF device.</li></ul>	<ul style="list-style-type: none"><li>If the synovium tissue between the labrum and the capsule is not cleaned, the plane cannot be identified. This will increase the risk of damaging the labrum.</li><li>Pointing the tip of the RF device toward the capsule instead of bone will result in capsule loss.</li></ul>

DALA, distal anterolateral accessory; RF, radiofrequency.



**Fig 1.** Patient positioned in the modified supine position for a right hip arthroscopy. Patient's head is to the right and feet to the left. \*Anterior inferior iliac spine. Three portals are identified: anterolateral (AL), midanterior (MA), and distal anterolateral accessory (DALA).

### Fluoroscopy Technique

1) The C-arm is positioned on the nonoperative side and draped in sterile fashion. 2) A true anterior-posterior radiograph of the pelvis is obtained by tilting the C-arm to compensate for the Trendelenburg inclination. Under fluoroscopy, the joint seal is broken, and traction is applied.

### Portals Placement

1) The anterolateral portal and midanterior (MA) portal are created as previously described.<sup>1</sup> 2) Diagnostic arthroscopy is performed to assess the presence of labral tearing, chondral damage, and other interarticular pathologies. 3) An additional distal anterolateral

accessory (DALA) is made to provide a better angle for capsule elevation (Fig 1).

### Capsulotomy

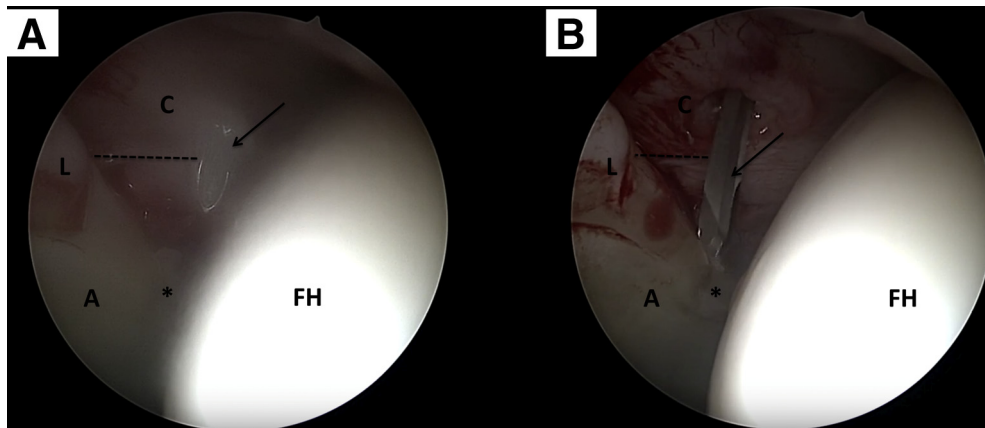
Maintaining an adequate margin of the acetabular capsular cuff is critical if the capsule is to be preserved later. The spinal needle's position is the first point of reference that the surgeon must use for this task (Fig 2A). Ideally,  $\geq 5$  mm of capsular cuff should be left intact (Fig 2B). From experience, the authors prefer to perform an interportal capsulotomy from the 12 to 2 o'clock position to connect the anterolateral and MA portals. After the diagnostic arthroscopy, the capsulotomy can be extended if extension of the labral tear beyond 12 to 2 o'clock position is found (Video).

### Diagnostic Arthroscopy and Labral Assessment

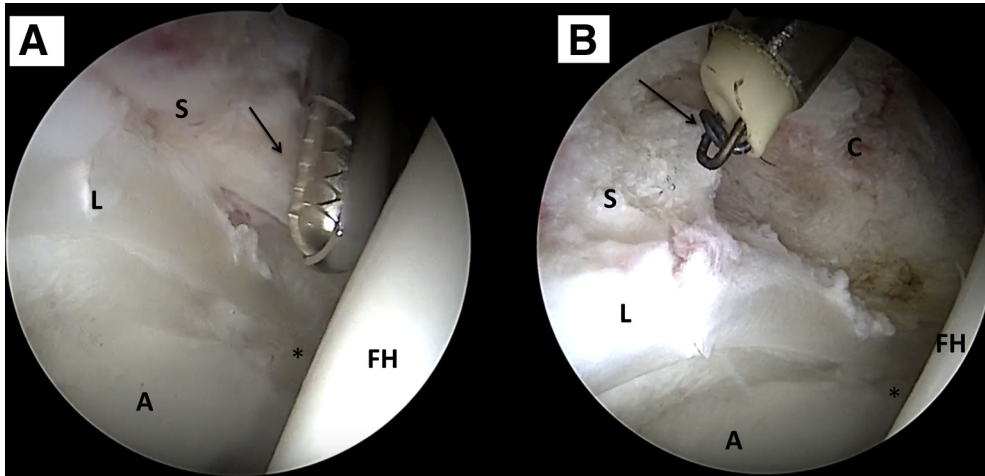
1) A systematic diagnostic arthroscopy is performed. 2) The ligamentum teres, acetabular notch, iliopsoas impingement sign, labral status, chondrolabral junction, and acetabular and femoral head cartilage are all assessed. 3) Elevation of the capsule is performed only after assessing the labral condition and confirming that refixation is required (Video).

### Identification of the Plane Between Labrum and Capsule

Identifying the plane between the labrum and the capsule is an important step. Synovium tissue frequently covers the plane between the labrum and the capsule and obscures the superior border of the labrum (Fig 3A). Failure to identify anatomy can result in irreversible labral damage. To avoid this, the synovium must be clear by careful shaving.



**Fig 2.** (A) Central compartment view from the anterolateral portal with the 70° arthroscope in a right hip. The spinal needle (black arrow) is inserted through the midanterior portal. At least 5 mm should be left from the tip of the spinal needle to the labrum (dotted line). (B) The beaver blade (black arrow) is inserted, and a cut parallel to the labrum is made from the 12 to 2 o'clock positions. Take care to leave  $\geq 5$  mm of capsular cuff during the procedure (dotted line). A, acetabulum; C, capsule; FH, femoral head; L, labrum. \*3 o'clock position.



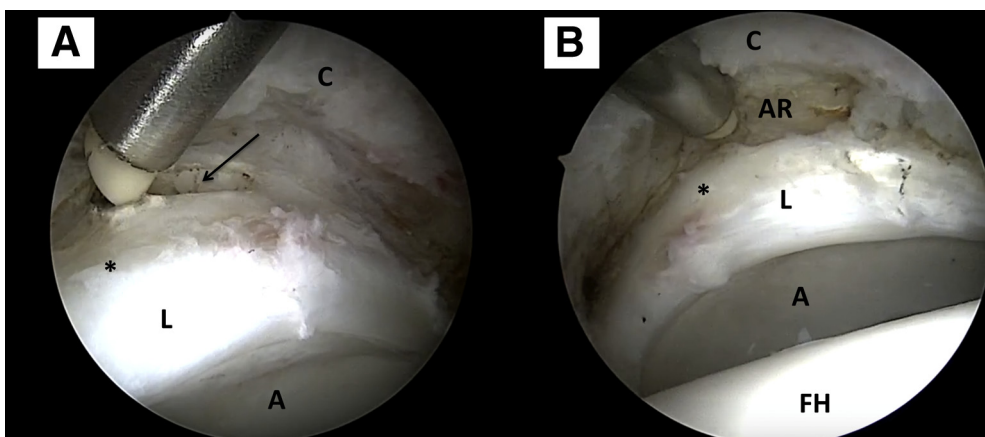
**Fig 3.** (A) Central compartment view from the anterolateral portal with the 70° arthroscope in a right hip. The shaver (black arrow) is inserted through the midanterior portal. Pointing away from the labrum, the shaver is used to remove the synovium tissue that covers the plane between capsule and labrum. (B) Once the synovium tissue has been partially removed, the radiofrequency wand (black arrow) is inserted through the distal anterior accessory portal, and full synovium tissue removal is accomplished. A, acetabulum; C, capsule; FH, femoral head; L, labrum; S, synovium. \*3 o'clock position.

Operate the shaver from the MA portal, being sure to direct the teeth away from the labrum. Tilt the teeth of the shaver toward the face of the camera to maintain visualization (Video). 1) Set the shaver suction to medium potency to decrease the shaver's aggressiveness. 2) At all times, maintain a clear view of the working field. Do not operate where visualization is compromised.

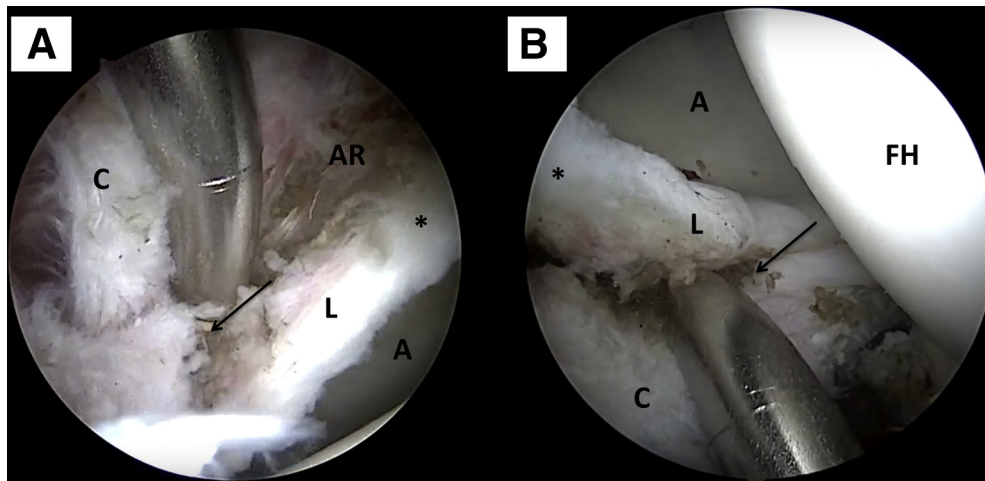
#### Radiofrequency Key Points During Elevation

Once the synovium is removed, replace the shaver with the 3.0-mm 50° radiofrequency (RF) wand.

1. The cleavage between the capsule and the superior labrum should be palpated and visualized. At this step, do not elevate the capsule while directly in contact with bone. Instead, place the tip of the wand 2 to 3 mm away from the capsule at the level of the capsule–labrum junction (Fig 3B). This maneuver will provide better visualization of the plane, reducing the risk of damaging the labrum and excess loss of capsular tissue (Video).
2. The extent of the capsule elevation will depend on the extent of the labral tear and bony work the acetabular rim requires. Once this is finished, reach



**Fig 4.** (A) View from the anterolateral portal with the 70° arthroscope in a right hip. The synovium tissue has been completely removed, revealing the plane between superior labrum and capsule. Keep the radiofrequency wand in the distal anterior accessory portal to expose the acetabular rim (black arrow). (B) Bird's eye view from the anterolateral portal. The acetabular rim has been exposed from the 12 to 2 o'clock position. A, acetabulum; AR, acetabular rim; C, capsule; FH, femoral head; L, labrum. \*3 o'clock position.



**Fig 5.** (A) View of the posterolateral labrum area from the anterolateral portal with the 70° arthroscope in a right hip. In this case, because of the extensive posterior labral tear, the acetabular rim must be further exposed. Note the capsule is thinner in this area, and extra care is needed to preserve the posterior capsule. (B) Keeping the 70° arthroscope in the anterolateral portal, the camera is turned 180°, which provides a better view of the posterolateral region. A, acetabulum; AR, acetabular rim; C, capsule; FH, femoral head; L, labrum; S, synovium. \*3 o'clock position.

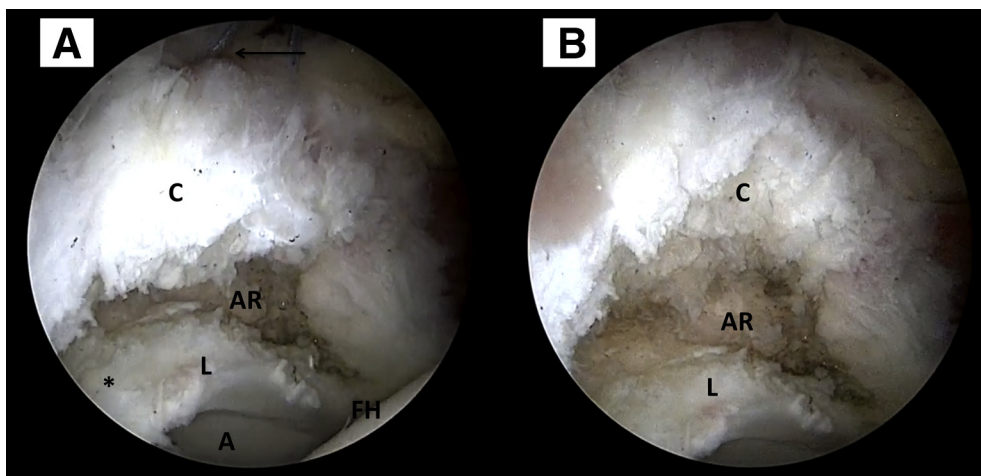
the bone at the appropriate level with the RF wand to expose the acetabular rim. Work medial to lateral (Fig 4).

3. Be cognizant that the posterolateral capsule, the region between 9 and 12 o'clock in a right hip, is generally considerably thinner than the anterior counterpart. Thus, particular attention is required to preserve the capsule in this region (Fig 5).
4. The amount of capsule that needs to be elevated from the acetabular rim depends on different factors such as type of femoroacetabular impingement, labral tear size, and acetabular coverage. A stitch placed between the 12 and 1 o'clock position of the capsule can provide better visualization of the acetabulum (Fig 6).

## Discussion

The importance of the capsule in hip arthroscopy is well established.<sup>1,5</sup> The hip capsule has an important role in hip biomechanics; therefore, minimizing iatrogenic damage during surgery is vital. Multiple authors have suggested that capsular repair may be a suitable approach for hip arthroscopy.<sup>6-8</sup> Different capsular management methods have been supported by several authors, differing chiefly on whether to perform capsular closure or plication.<sup>9,10</sup>

There is a lack, however, of technical information in the literature regarding how to reproducibly and safely perform a capsular elevation. Technical knowledge of this step should not be taken for granted. We truly feel



**Fig 6.** (A) View from the anterolateral portal with the 70° arthroscope in a right hip. A traction stitch with a 2.0 Fiberwire (Arthrex) is placed between the 12 and 1 o'clock position to maintain exposure of the acetabular rim. (B) Tension is applied to the traction stitch. The result of the capsule elevation along with a preserved capsule can be seen. A, acetabulum; AR, acetabular rim; C, capsule; FH, femoral head; L, labrum; S, synovium. \*3 o'clock position.

that this is a demanding procedure, especially in the early portion of the hip arthroscopy learning curve. As such, the purpose of this note is to provide a detailed, stepwise capsule elevation technique for hip arthroscopy.

Capsular treatment is especially relevant when patients are borderline dysplastic or have ligamentous laxity.<sup>10,11</sup> Lodhia et al.<sup>12</sup> found in a systematic review that hip arthroscopy alone with capsular plication improved outcomes at short- and mid-term follow-up in patients with borderline dysplasia. Recently, Larson et al.<sup>10</sup> reported a 32% failure rate after hip arthroscopy for treatment of borderline hip dysplasia. In this series, the mean preoperative lateral center-edge angle was 20.8° (range, 8.7° to 24.5°). When capsular plication was performed, they noted that the failure rate dropped by 56.25%. Similar findings have been published by others.<sup>1,13-15</sup> To accomplish these results, the capsule must be preserved.

In conclusion, capsular elevation is essential for hip arthroscopy. Although it may be technically challenging early in the learning curve, it can be performed in a safe and efficient manner by following the detailed steps presented in this Technical Note.

## References

- Maldonado DR, Perets I, Mu BH, et al. Arthroscopic capsular plication in patients with labral tears and borderline dysplasia of the hip: Analysis of risk factors for failure. *Am J Sports Med* 2018;46:3446-3453.
- Byrd JWT, Jones KS. Hip arthroscopy for labral pathology: Prospective analysis with 10-year follow-up. *Arthroscopy* 2009;25:365-368.
- Menge TJ, Briggs KK, Dornan GJ, McNamara SC, Philippon MJ. Survivorship and outcomes 10 years following hip arthroscopy for femoroacetabular impingement: Labral debridement compared with labral repair. *J Bone Joint Surg Am* 2017;99:997-1004.
- Domb BG, Martin TJ, Gui C, Chandrasekaran S, Suarez-Ahedo C, Lodhia P. Predictors of clinical outcomes after hip arthroscopy: A prospective analysis of 1038 patients with 2-year follow-up. *Am J Sports Med* 2018;46:1324-1330.
- Matsuda DK. Editorial commentary: Hip capsule: To repair or not? *Arthroscopy* 2017;33:116-117.
- Ortiz-Declet V, Mu B, Chen AW, et al. Should the capsule be repaired or plicated after hip arthroscopy for labral tears associated with femoroacetabular impingement or instability? A systematic review. *Arthroscopy* 2018;34:303-318.
- Riff AJ, Kunze KN, Movassaghi K, et al. Systematic review of hip arthroscopy for femoroacetabular impingement: The importance of labral repair and capsular closure. *Arthroscopy* 2019;35:646-656.e3.
- Domb BG, Chaharbakhshi EO, Perets I, Walsh JP, Yuen LC, Ashberg LJ. Patient-reported outcomes of capsular repair versus capsulotomy in patients undergoing hip arthroscopy: Minimum 5-year follow-up—a matched comparison study. *Arthroscopy* 2018;34:853-863.e1.
- Chandrasekaran S, Vemula SP, Martin TJ, Suarez-Ahedo C, Lodhia P, Domb BG. Arthroscopic technique of capsular plication for the treatment of hip instability. *Arthrosc Tech* 2015;4:e163-e167.
- Larson CM, Ross JR, Stone RM, et al. Arthroscopic management of dysplastic hip deformities: predictors of success and failures with comparison to an arthroscopic FAI cohort. *Am J Sports Med* 2016;44:447-453.
- Cvetanovich GL, Levy DM, Weber AE, et al. Do patients with borderline dysplasia have inferior outcomes after hip arthroscopic surgery for femoroacetabular impingement compared with patients with normal acetabular coverage? *Am J Sports Med* 2017;45:2116-2124.
- Lodhia P, Chandrasekaran S, Gui C, Darwish N, Suarez-Ahedo C, Domb BG. Open and arthroscopic treatment of adult hip dysplasia: A systematic review. *Arthroscopy* 2016;32:374-383.
- Evans PT, Redmond JM, Hammarstedt JE, Liu Y, Chaharbakhshi EO, Domb BG. Arthroscopic treatment of hip pain in adolescent patients with borderline dysplasia of the hip: Minimum 2-year follow-up. *Arthroscopy* 2017;33:1530-1536.
- Chandrasekaran S, Darwish N, Chaharbakhshi EO, Lodhia P, Suarez-Ahedo C, Domb BG. Arthroscopic treatment of labral tears of the hip in adolescents: Patterns of clinical presentation, intra-articular derangements, radiological associations and minimum 2-year outcomes. *Arthroscopy* 2017;33:1341-1351.
- Chandrasekaran S, Darwish N, Martin TJ, Suarez-Ahedo C, Lodhia P, Domb BG. Arthroscopic capsular plication and labral seal restoration in borderline hip dysplasia: 2-Year clinical outcomes in 55 cases. *Arthroscopy* 2017;33:1332-1340.