



ELSEVIER

# Hip and Pelvic Problems in Athletes

Michael K. Shindle, MD, Benjamin G. Domb, MD, and Bryan T. Kelly, MD

In the athletic population, the differential diagnosis of hip pain is quite broad and must include intra-articular pathology, extra-articular pathology, and central pubic pain associated with athletic pubalgia. In addition to an appropriately performed history and physical examination, advanced imaging techniques, including magnetic resonance imaging (MRI) and ultrasound, often are required to narrow the differential diagnosis. MRI is an excellent modality to image the pelvis and hip because of its ability to screen the pelvis for other etiologies of pain, its superior soft-tissue contrast, which allows visualization of the articular cartilage, fibrocartilaginous labrum, and myotendinous junctions, and its lack of ionizing radiation. During the last decade, the management of hip injuries has evolved substantially as a result of the advancement in techniques and flexible instrumentation for hip arthroscopy. Currently, a variety of hip pathologies may be addressed arthroscopically, including labral tears, loose bodies, femoroacetabular impingement, coxa saltans, ligamentum teres injuries, and capsular laxity. This article will focus on common etiologies of hip and pelvis pain in the athletic population with an emphasis on the use of hip arthroscopy to treat these disorders.

Oper Tech Sports Med 15:195-203 © 2007 Elsevier Inc. All rights reserved.

**KEYWORDS** hip arthroscopy, labral tears, femoroacetabular impingement, hip instability

Hip injuries are very prevalent in the athletic population. Although they are most commonly related to extra-articular muscular strains or sprains, intra-articular lesions affecting the acetabular labrum, articular cartilage, and capsular and ligamentous structures are frequently the cause of recalcitrant hip pain that may be difficult to accurately diagnose.<sup>1</sup> The management of hip injuries has evolved substantially with the advancement in diagnostic tools, such as magnetic resonance imaging (MRI) and with new techniques and flexible instrumentation for hip arthroscopy. Hip injuries can be divided into extra-articular, intra-articular, or central pubic pain associated with athletic pubalgia. Labral tears, frequently associated with femoroacetabular impingement (FAI), are the most common cause of disabling intra-articular hip pain in the athletic population.<sup>2,3</sup> Currently, various hip pathologies can be addressed arthroscopically, including labral tears, loose bodies, FAI, coxa saltans, ligamentum teres injuries, and capsular laxity.<sup>4</sup> This article will focus on common etiologies of hip pain in athletes with an emphasis on the use of hip arthroscopy to treat these disorders.

## History and Physical Examination

The differential diagnosis of hip pain is quite broad in the athletic population (Table 1). Without an appropriate workup, hip pain in an athlete should not be attributed to muscle strains or soft tissue contusions. A detailed history and physical examination are required in an attempt to narrow the differential diagnosis (Table 1). A key goal of physical examination is to determine if the pain is of intra-articular or extra-articular origin. The history should include the qualitative nature of the discomfort (clicking, catching, stiffness, instability, decreased performance, and weakness), the location of the discomfort, onset of symptoms, and any history of trauma or developmental abnormality. In addition, risk factors for avascular necrosis or stress fractures should be assessed as well as any details that suggest referred or systemic causes of hip pain.<sup>4</sup>

Palpation of specific regions of the hip may localize tenderness with extra-articular pathology, but rarely with intra-articular pathology.<sup>5</sup> It should be noted that intra- and extra-articular pathologies commonly coexist, which may complicate the workup and diagnosis. A complete neurovascular examination should be performed, and gait, posture, muscle contractures, limb-length inequality, and scoliosis should be assessed. Active and passive range of motion should be

Hospital for Special Surgery, New York, NY.  
Address reprint requests to Bryan T. Kelly, MD, ATTN: Katrina Dela Torre,  
MSN, Belaire Building, 525 East 71st Street, New York, NY 10021.

**Table 1** Differential Diagnosis of Hip Pain

|  |  |
|--|--|
| <b>Traumatic</b>                         | <b>Nonmusculoskeletal causes</b>               |
| Subluxation/dislocation                  | Psoas muscle abscess                           |
| Stress fracture/fracture                 | Spine  |
| Hematoma                                 | Hernia   |
| Contusion                                | Endometriosis                                  |
|  | Ovarian cyst                                   |
|  | Peripheral vascular disease                    |
| <b>Labral Pathology</b>                  | <b>Unknown etiology</b>                        |
| Femoroacetabular impingement             | Transient osteoporosis of the hip              |
| Hypermobility                            | Bone marrow edema syndrome                     |
| Trauma                                   |  |
| Dysplasia                                |  |
| <b>Infectious/tumor/metabolic</b>        | <b>Synovial proliferative disorders</b>        |
| Septic arthritis                         | Pigmented villonodular synovitis               |
| Osteomyelitis                            | Synovial chondromatosis                        |
| Benign bone and soft-tissue neoplasms    | Chondrocalcinosis                              |
| Malignant bone and soft-tissue neoplasms |  |
| Metastatic bone disease                  |  |
| <b>Inflammatory</b>                      | <b>Metabolic</b>                               |
| Rheumatoid arthritis                     | Paget's disease                                |
| Reiter's syndrome                        | Primary hyperparathyroidism                    |
| Psoriatic arthritis                      |  |
| <b>Chondral pathology</b>                | <b>Extra-articular pathology</b>               |
| Lateral impaction                        | Coxa saltans (internal/external)               |
| Avascular necrosis                       | Psoas impingement                              |
| Loose bodies                             | Abductor tears (Rotator cuff tears of the hip) |
| Chondral shear injury                    | Athletic pubalgia                              |
| Osteoarthritis                           | Trochanteric bursitis                          |
|  | Ischial bursitis                               |
| <b>Capsule Pathology</b>                 | Osteitis pubis                                 |
| Laxity                                   | Piriformis syndrome                            |
| Adhesive capsulitis                      | Sacroiliac pathology                           |
| Synovitis/inflammation                   | Tendonitis (hip flexors, abductors, adductors) |

evaluated with patient in the seated, supine, and prone positions.<sup>5</sup>

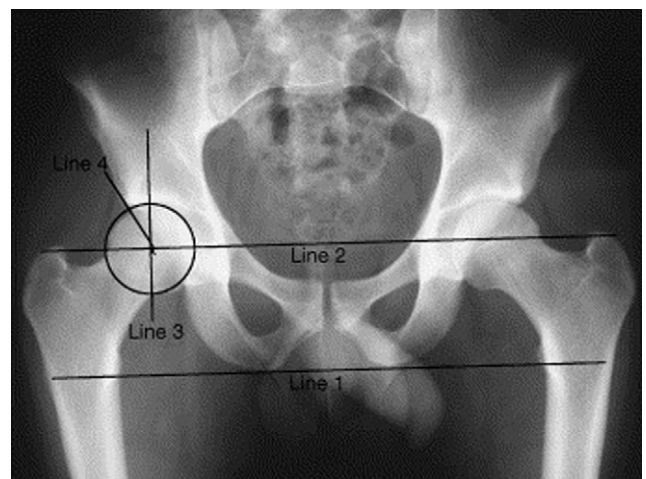
Specific tests that can be performed include the Thomas test to evaluate for the presence of a hip flexion contracture.<sup>6,7</sup> Pain with log rolling of the lower extremity is suggestive of intra-articular hip pain.<sup>7,8</sup> The flexion-abduction-external rotation (FABER) test is performed by placing the ankle on the affected side across the unaffected thigh (figure-of-4 position). Classically, a painful FABER test has been felt to suggest pathology of the sacroiliac joint when the symptoms are referred posteriorly.<sup>7</sup> Patients with anterior hip pain in this position may have injury or irritation to the anterior capsule, labrum, or psoas. FAI or labral tears may be associated with pain in the position of flexion-adduction-internal rotation

(FADDIR test or impingement test) as well as groin pain or clicking.<sup>9</sup>

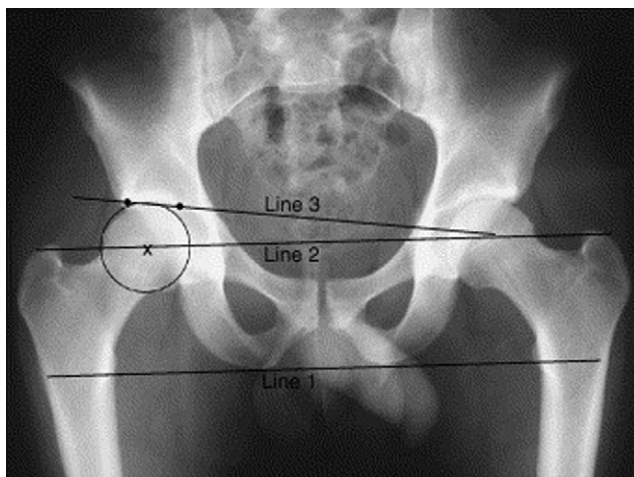
## Imaging Studies

Wenger and coworkers demonstrated that in 87% of patients with labral tears, there is evidence of osseous abnormalities detected on plain radiographs.<sup>10</sup> In an athlete presenting with hip pain, we routinely obtain an anteroposterior (AP) pelvis, false profile view, and Dunn lateral view (elongated neck lateral).<sup>11</sup> The AP pelvis view should be obtained in slight internal rotation and with standardized pelvic inclination. Siebenrock and coworkers recommend that the correct pelvic inclination is indicated by the distance between the pubic symphysis and sacrococcygeal joint (approximately 32 mm in men and 47 mm in women).<sup>12</sup> It is important to note that variations in pelvic inclination or rotation may change the apparent anteversion of the acetabulum. An increase in pelvic inclination will cause an apparent decrease in anteversion, whereas decreased inclination will cause an apparent increase in anteversion.<sup>12</sup> The osseous landmarks should be identified, including the iliopectineal line, the ilioischial line, anterior and posterior acetabular walls, the sourcil (acetabular roof), and tear drop. The cortical integrity and trabecular pattern of the femoral neck should be carefully evaluated to exclude a nondisplaced fracture. Radiographic indices should include the femoral neck-shaft angle, the center-edge angle of Wiberg (Fig. 1), and the Tönnis angle (Fig. 2).<sup>13</sup> AP x-rays should also be evaluated for signs of acetabular retroversion (Fig. 3).<sup>13</sup> A false profile view is useful for evaluating anterior femoral head coverage and a Dunn lateral view (90° flexion, 20° abduction) is useful for identifying a CAM lesion or an abnormally shaped anterior head-neck junction.<sup>11</sup>

In most cases, an MRI is indicated to evaluate the acetabular labrum, articular cartilage, and to screen the pelvis for other etiologies of pain. At our institution, the axial proton density and coronal inversion recovery body coil



**Figure 1** An AP radiograph showing the method for measuring the center-edge angle of Wiberg. The center-edge angle is normally >25°, with 20° to 25° considered borderline. (Reprinted with permission from Shindle et al.<sup>13</sup>)



**Figure 2** An AP radiograph showing the method for measuring the Tönnis angle of the hip; a normal Tönnis angle is  $<10^\circ$ . Increased Tönnis angles are associated with lateral subluxation of the hip and increased contact pressures of the femoral head on the anterosuperior weight bearing zone of the acetabulum. (Reprinted with permission from Shindle et al.<sup>13</sup>)

images are followed by the use of a surface coil technique with cartilage-sensitive, intermediate-echo time, fast-spin-echo pulse sequences in the coronal, sagittal, and oblique axial (SWISS protocol) planes, with high in-plane and slice resolution.

Evaluation of patients with osseous abnormalities can often be facilitated with a computed tomography scan with three-dimensional reconstructed images. These images allow accurate assessment of CAM and pincer lesions as well as femoral and acetabular version. A complete appreciation for the bony anatomy is necessary for preoperative planning and surgical decision making.

Finally, fluoroscopically guided intraarticular injection is an invaluable tool to determine whether hip pain is due to an intraarticular derangement. Byrd and coworkers have demonstrated that pain relief to an intraarticular injection is a 90% reliable indicator of an intraarticular abnormality.<sup>14</sup>

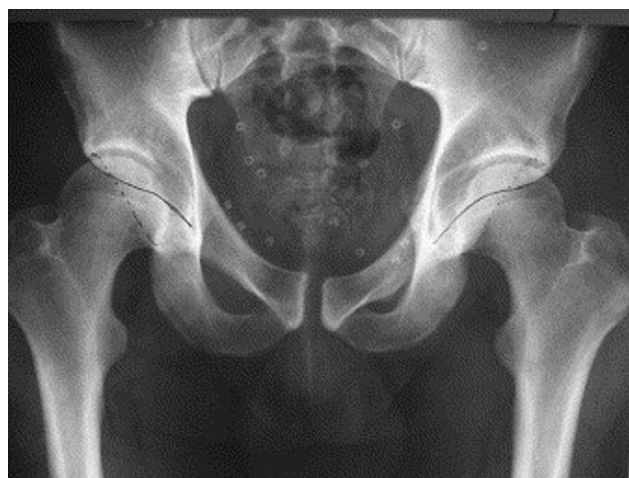## Labral Tears

Injuries to the acetabular labrum are the most consistent pathologic findings identified during hip arthroscopy.<sup>15</sup> The labrum is a fibrocartilaginous structure that provides some structural resistance to lateral and vertical motion of the femoral head within the acetabulum and has an important sealing function which limits fluid expression from the joint space to protect the cartilage layers of the hip.<sup>16-18</sup> Mechanical symptoms and restricted range of motion are usually present with labral tears. Patients with clinical signs, MR findings consistent with a labral tear, and persistent hip pain for more than 6 weeks are candidates for hip arthroscopy.<sup>15</sup> To optimize the outcome results, the etiology for labral pathology should be identified. Common etiologies include trauma, FAI, dysplasia, psoas impingement, and atraumatic instability.<sup>4,14</sup>

Labral tears in the athletic population occur mainly in the anterior–superior zone in association with FAI and traumatic events occurring during contact sports. In these athletes, some combination of a bony predisposition for mechanical overload (ie, FAI or dysplasia, or both) and aggressive sporting activities that aggravate the underlying osseous anatomy, increase the likelihood of intraarticular injury. Seldes and coworkers<sup>19</sup> has described 2 histological types of labral tears. A type 1 labral tear is a detachment at the fibrocartilaginous labrum–cartilage junction (Fig. 4), while a type 2 tear is an intrasubstance tear (Fig. 5).<sup>19,20</sup> Labral tears associated with CAM impingement are more commonly type 1 tears affecting the transition zone cartilage and articular surface of the labrum. Pincer lesions, on the other hand, are usually associated with type 2 tears secondary to crushing of the labrum against the neck of the femur.

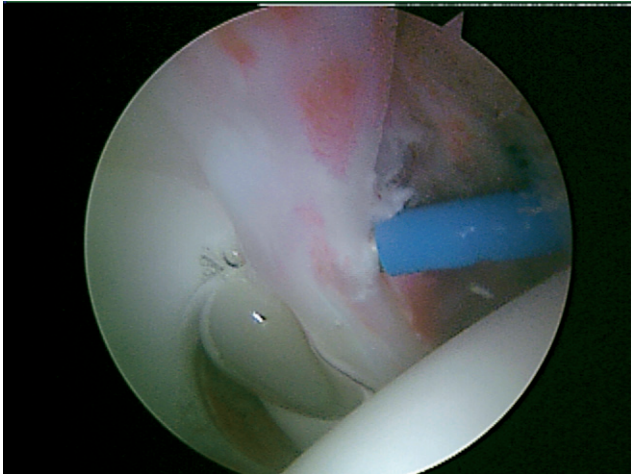
In our experience, some patients have history and physical examination findings consistent with coxa saltans and have symptomatic relief with sonography-guided iliopsoas injections.<sup>21</sup> In this population, the labral pathology may occur in an atypical direct anterior location in the absence of bony abnormalities. We believe this direct anterior injury may be related to compression of the anterior capsulo-labral complex by the psoas tendon as it crosses the anterior acetabular rim. Labral debridement or repair combined with fractional lengthening of the psoas has led to subjective improvement in symptoms in the short term. However, longer follow-up is required to validate this procedure.

For surgical treatment, we prefer the supine position, which has been well described.<sup>6,8,22</sup> We use an anterior and an anterolateral portal, as well as posterolateral, distal lateral accessory, and other portals as needed.<sup>15</sup> To maximize visualization, we use a combination of  $70^\circ$  and  $30^\circ$  scopes. After a systematic diagnostic arthroscopy is performed, the labrum and capsule-labral junction are probed to rule out detachment. If required to improve visualization, a partial



**Figure 3** An AP radiograph of the pelvis shows the crossover sign indicative of a retroverted acetabulum. In a retroverted acetabulum, the anterior acetabular rim (dashed line) crosses over the posterior acetabular rim (solid line). (Reprinted with permission from Shindle et al.<sup>13</sup>)





**Figure 4** Type I labral tear with full-thickness detachment off the rim of the acetabulum.<sup>20</sup>

synovectomy is performed with a radiofrequency device. The majority of the vascular supply to the labrum is provided from the capsular contribution whereas the articular surface of the labrum has a limited synovial covering and decreased vascularity.<sup>23</sup> The goal of surgical treatment of labral tears is to eliminate any unstable tissue by debridement or repair, while preserving as much healthy tissue as possible to allow the labrum to maintain its role as a suction seal and secondary joint stabilizer.<sup>20</sup> When possible, a tear at the articular margin should be repaired with suture anchors to the acetabular rim (Fig. 6).<sup>20</sup> Frayed or degenerative labral tears should be debrided to stable edges with a combination of RF probes and motorized shavers.

## Femoroacetabular Impingement

Two distinct types of FAI have been described, CAM and pincer.<sup>24-26</sup> Although the 2 types of FAI can occur in isolation, it has recently been shown that combined impingement occurs in 86% of cases.<sup>27</sup> Cam impingement is the result of an abnormally shaped femoral head, which contacts a normal spherical acetabulum, most commonly in hip flexion and internal rotation. When the aspherical head-neck junction of the femur enters the acetabulum, it displaces the labrum toward the capsule and applies disproportionate load to the adjacent articular cartilage of the acetabulum. This leads to chondral delamination and detachment of the labrum from the acetabular rim.

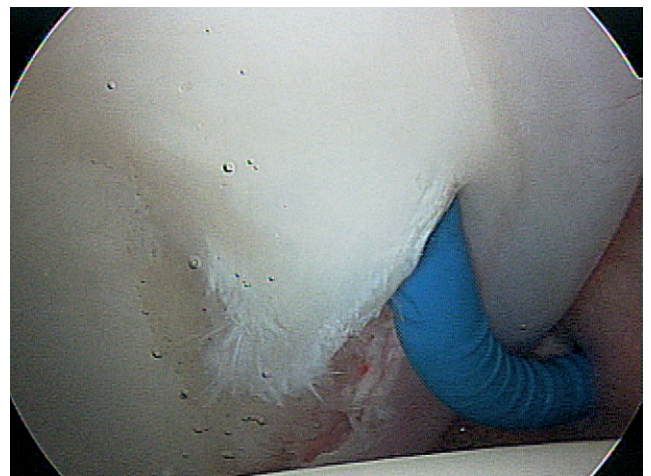
Pincer impingement involves an abnormal acetabulum with retroversion or overcoverage of the femoral head. This retroversion or overcoverage causes impingement of the labrum between the acetabulum and the femoral neck, resulting in crushing, degeneration, and eventual ossification of the labrum. Chondral injuries are generally less severe than in cam impingement.<sup>28,29</sup>

Philippon and coworkers have demonstrated that FAI is a major cause of hip pain, reduced range of motion and decreased performance in the athletic population.<sup>15,28</sup> Such injuries are common in a broad range of sports, including

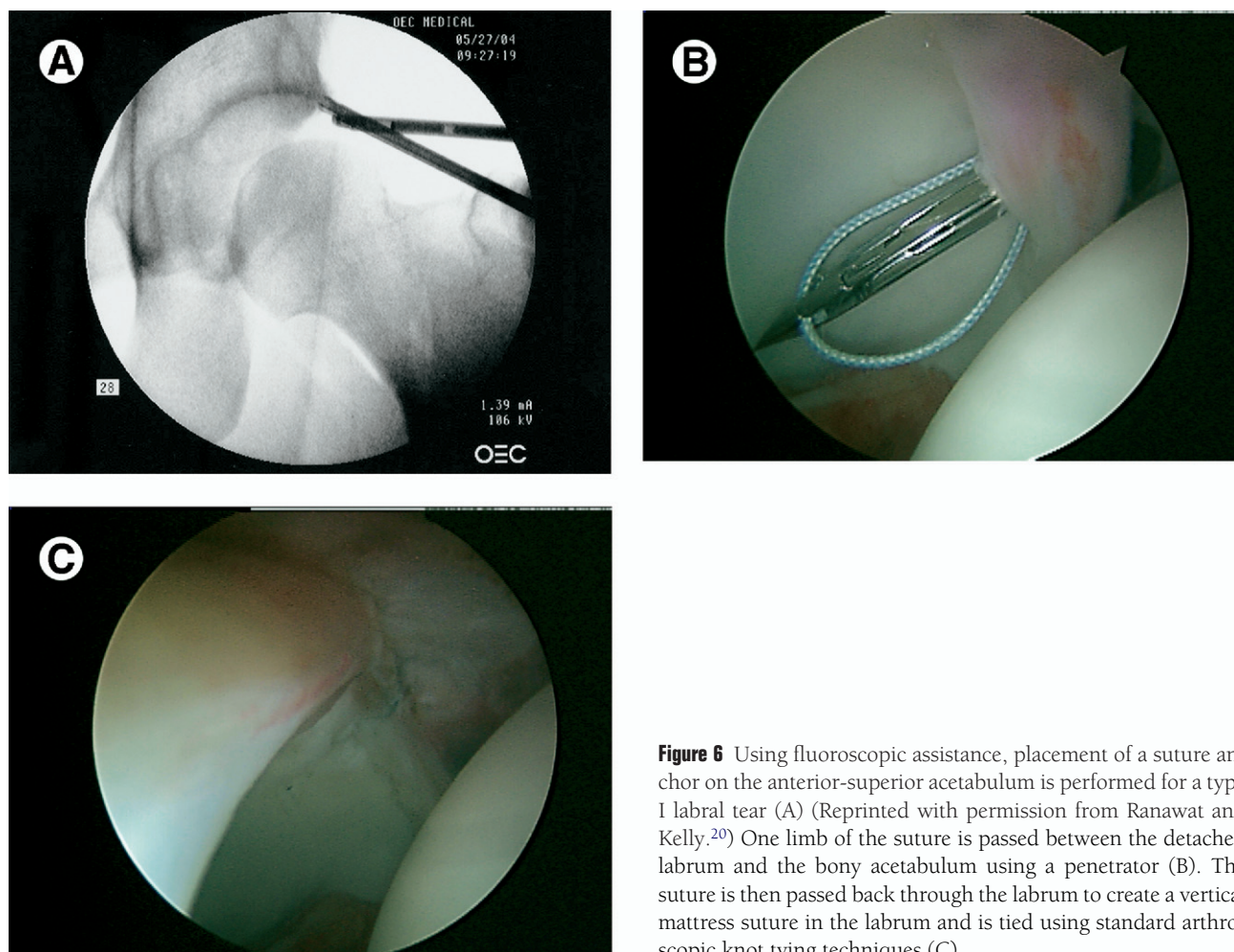
hockey, ballet, football, and soccer. In 33 competitive ice hockey players undergoing hip arthroscopy, 27 (81%) required decompression of FAI.<sup>28</sup> Athletes usually present with anterior groin pain exacerbated by hip flexion, and physical examination reveals the “impingement sign.” MRI usually demonstrates an anterosuperior labral tear, and an anterosuperior cartilage defect (Fig. 7).

During hip arthroscopy, the standard portals are established and the intraarticular pathology is addressed while the hip is under traction. This may include labral debridement or repair, microfracture, and chondroplasty. Anterior overcoverage secondary to a pincer lesion can also be treated arthroscopically, either from the central or peripheral compartments.<sup>28</sup> First, the margins of the pincer lesion must be defined by probing with a flexible instrument. This lesion is usually associated with a flattened, degenerative or cystic labrum. In small pincer lesions in association with a cam lesion, addressing only the cam lesion may provide sufficient clearance.<sup>28</sup> However, larger pincer lesions require bony resection. This “rim trimming” procedure may necessitate detachment of the labrum overlying the pincer lesion. Resection can generally be considered complete when the crossover sign is eliminated on fluoroscopy. Resecting greater than 5 mm of acetabular rim is not recommended, as it may cause instability.<sup>28</sup> After this resection, the labrum should be reattached to the acetabular rim using suture anchors as previously described in this chapter.

For decompression of the femoral-head neck junction, we recommend a distal lateral accessory portal.<sup>15</sup> After traction has been slowly released and the knee is flexed to 45°, the arthroscope is placed in the anterior portal and a skin incision is made approximately 4 cm distal and 1 cm anterior to the anterolateral portal.<sup>28</sup> While the hip is flexed and in neutral rotation, the arthroscope placed anteriorly and distally over the femoral head peripheral to the labrum, providing excellent visualization of the head-neck junction. A long motorized burr is used under fluoroscopy to perform osteoplasty of the CAM lesion. The hip may be flexed and extended, ab-



**Figure 5** Arthroscopic images demonstrating repair of a type II labral tear with an intrasubstance split in the tissue. (Reprinted with permission from Ranawat and Kelly.<sup>20</sup>)



**Figure 6** Using fluoroscopic assistance, placement of a suture anchor on the anterior-superior acetabulum is performed for a type I labral tear (A) (Reprinted with permission from Ranawat and Kelly.<sup>20</sup>) One limb of the suture is passed between the detached labrum and the bony acetabulum using a penetrator (B). The suture is then passed back through the labrum to create a vertical mattress suture in the labrum and is tied using standard arthroscopic knot tying techniques (C).

ducted and adducted, and internally and externally rotated to determine the appropriate positioning.<sup>28</sup> After osteoplasty, joint clearance should be assessed by flexing the hip beyond 90° and internally rotating under direct visualization. The superior and posterolateral aspects of the femoral head-neck junction should be avoided because branches of the medial circumflex artery perforate the joint capsule and course along this region of the femoral neck. A resection of less than 30% of the head-neck junction is recommended because this has been shown to not alter the load bearing capacity of the femoral neck.<sup>30</sup> Philippon and coworkers report that burring to a depth of approximately 5 to 8 mm has been a safe and effective procedure.<sup>28</sup>

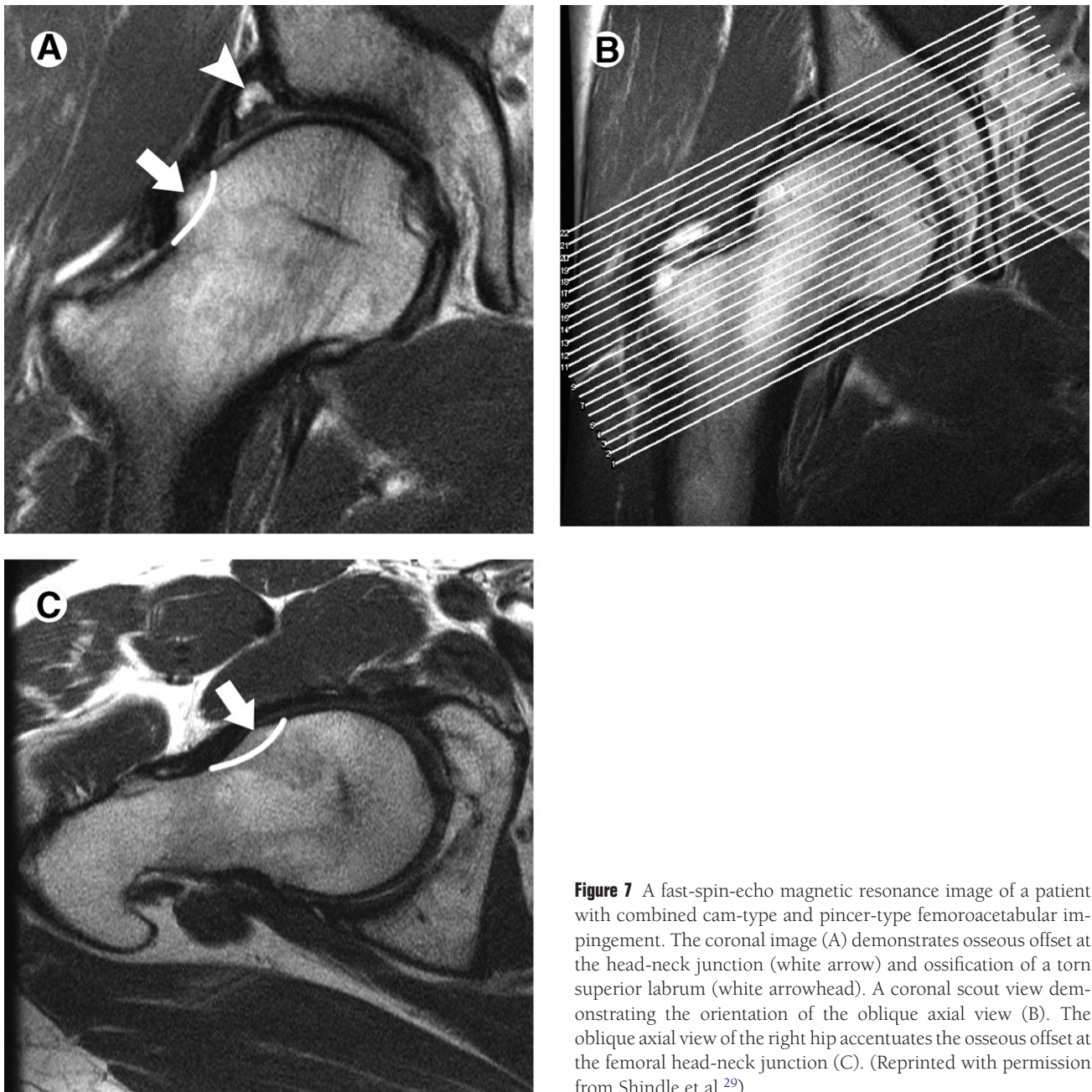
## Hip Instability

Hip instability can be traumatic or atraumatic in nature. Traumatic instability ranges from subluxation to dislocation. Hip dislocations are most commonly associated with dashboard injuries in motor vehicle accidents, but also have been reported in American football, rugby, skiing, jogging, basketball, soccer, biking, and gymnastics.<sup>31-33</sup> The initial phase of management involves rapid reduction and, when indicated, aspiration of hemarthrosis, to minimize long-term complica-

tions such as osteonecrosis. The secondary phase focuses on definitive care of injured structures.<sup>34-36</sup> Most hip dislocations sustained during athletic activities are pure dislocations and, due to the low energy mechanism, usually have no associated fractures or small acetabular rim fractures. Thus, surgical stabilization is often not warranted and active and passive range of motion can begin as soon as tolerated by the patient. Hip arthroscopy is playing a growing role in treatment of femoral head pathology, loose bodies, chondral injuries and labral pathology associated with hip dislocations. The optimal timing of the procedure is debatable due to the concern over the effects of traction during the acute phase of injury. If a loose body is not present, we feel that hip arthroscopy should be delayed for at least 6 weeks so that a repeat MRI can be performed to rule out the presence of early osteonecrosis before placing the hip in traction. However, if a significant loose body is present, hip arthroscopy is an option and may decrease the incidence of posttraumatic arthritis.<sup>37</sup>

Traumatic posterior hip subluxation has a more subtle presentation and may occur with seemingly minimal trauma. The physician should have a high index of suspicion for an intra-articular injury even after minor trauma. The mechanism is often similar to a hip dislocation with a fall on a flexed hip and knee with a posteriorly directed force. Radiographic





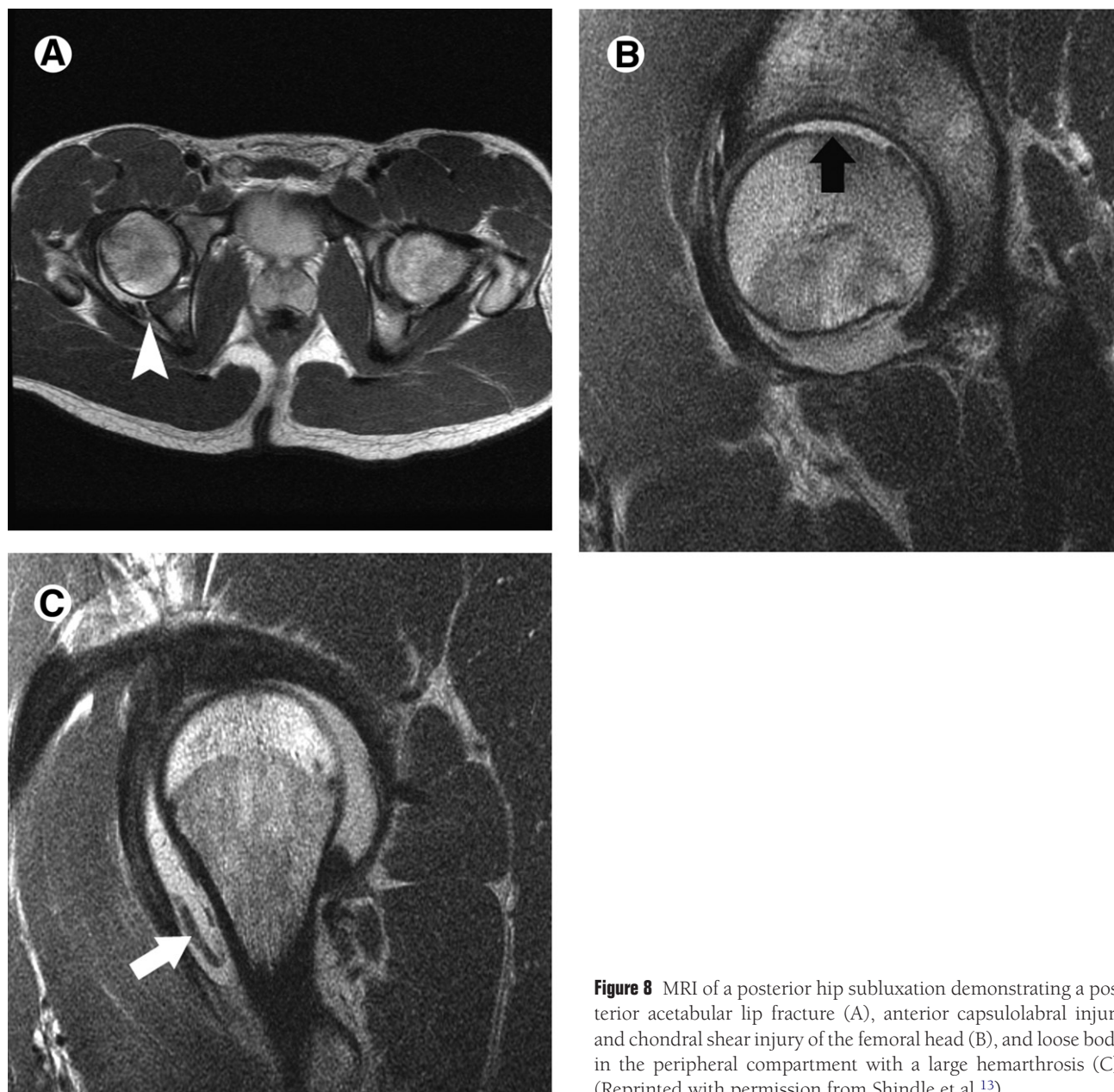
**Figure 7** A fast-spin-echo magnetic resonance image of a patient with combined cam-type and pincer-type femoroacetabular impingement. The coronal image (A) demonstrates osseous offset at the head-neck junction (white arrow) and ossification of a torn superior labrum (white arrowhead). A coronal scout view demonstrating the orientation of the oblique axial view (B). The oblique axial view of the right hip accentuates the osseous offset at the femoral head-neck junction (C). (Reprinted with permission from Shindle et al.<sup>29</sup>)

evaluation should include an AP pelvis and Judet views to evaluate for a “posterior lip fracture.” The evaluation should also include an MRI that may demonstrate the characteristic triad of findings described by Moorman and coworkers: hemarthrosis, posterior acetabular lip fracture, and iliofemoral ligament disruption (Fig. 8).<sup>38</sup> The presence of a significant hemarthrosis may warrant aspiration under fluoroscopy to decrease intracapsular pressure. An MRI is also useful to detect osteonecrosis and help determine which patients may return safely to sports activity. A general treatment algorithm for the management of traumatic hip instability is outlined in Fig. 9.<sup>13</sup>

Atraumatic instability may arise from overuse injuries leading to microinstability or from generalized ligamentous laxity. Overuse injuries are common in athletes who participate in sports involving repetitive hip rotation with axial

loading, such as golf, figure skating, football, baseball, ballet, martial arts, and gymnastics. The history provides the greatest clue to the diagnosis because athletes can usually describe the motion that reproduces the pain.<sup>13,39</sup> The labrum or iliofemoral ligament may be damaged or stretched by these repetitive forces. This can lead to painful labral injury, capsular redundancy, and subsequent microinstability. With compromised static stabilizers, including the capsule, iliofemoral ligament and labrum, the hip must rely more on its dynamic stabilizers. This can result in a cascade of disorders. For example, the resulting chronically contracted or tight psoas major can in turn cause low back pain, coxa saltans, and a crushing injury to the direct anterior labrum.<sup>40</sup>

The spectrum of atraumatic instability also includes patients with hip pain secondary to more generalized ligamen-



**Figure 8** MRI of a posterior hip subluxation demonstrating a posterior acetabular lip fracture (A), anterior capsulolabral injury and chondral shear injury of the femoral head (B), and loose body in the peripheral compartment with a large hemarthrosis (C). (Reprinted with permission from Shindle et al.<sup>13</sup>)

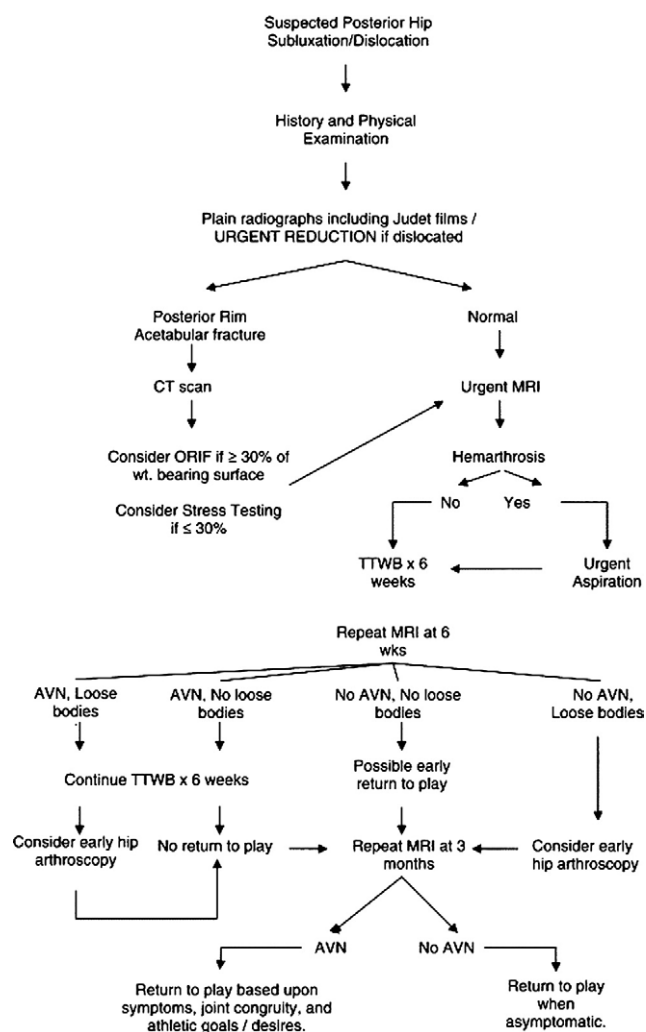
tous laxity, or, in the extreme form, in patients with connective tissue disorders such as Ehlers–Danlos syndrome or Marfan’s syndrome.<sup>39</sup>

The treatment of atraumatic hip instability is still debatable. Initial treatment should consist of conservative treatment with antiinflammatories and physical therapy in an attempt to break the cycle of painful capsule–labral irritation. If pain is persistent and intraarticular anesthetic injection provides relief, arthroscopic treatment may be considered. The goals of arthroscopy are anatomic restoration of the labrum and a reduction in capsular laxity. This may be accomplished by thermal modification of collagen in the hip capsular tissue combined with labral repair versus debridement. Focal thermal capsulorrhaphy is performed using three passes in a cornfield pattern with a flexible probe at a temperature of 67°C and power of 40 W.<sup>39</sup> If capsular redundancy is still

present after this procedure, then capsular plication should be performed to imbricate the medial and lateral limbs of the iliofemoral ligament.

## Rehabilitation

A successful outcome of hip arthroscopy is highly dependent on postoperative rehabilitation. Depending on the extent of bony resection and the presence of labral refixation, patients are restricted to 20 pounds foot-flat weight-bearing activity for between 10 days and 4 weeks. Our protocol includes continuous passive motion for the first 4 weeks for 2 to 4 hours per day. Starting immediately postoperatively, patients are encouraged to ride a stationary bike with a high seat to avoid pinching. A slow progression to full strength and activity occurs over a three to four month period. This avoids



**Figure 9** Treatment algorithm for athletic hip dislocation or subluxation. (Reprinted with permission from Shindle et al.<sup>13</sup>)

over activation or aggressive loading of the hip flexors, abductors, and adductors, as these muscle groups are highly susceptible to fatigue and tendonitis postoperatively. Although full return to sporting activity is anticipated by 5 to 6 months, patients may continue to see improvement in their symptoms for up to a year postoperatively.

## Conclusions

There is a vast array of hip and pelvic problems that may affect an athlete and decrease performance. Hip arthroscopy is a rapidly evolving field that offers minimally invasive treatment options for a wide spectrum of pathology. In the short term, many disorders have been treated successfully. Further study is necessary to establish the indications and long-term effectiveness of these procedures.

## References

- Burnett RS, Della Rocca GJ, Prather H, et al: Clinical presentation of patients with tears of the acetabular labrum. *J Bone Joint Surg Am* 88:1448-1457, 2006
- Byrd JW, Jones KS: Hip arthroscopy in athletes. *Clin Sports Med* 20: 749-761, 2001
- Philippon M: Arthroscopy of the hip in the management of the athlete, in McGinty J (ed): *Operative Arthroscopy*. Philadelphia, Lippincott-Raven, 2003, pp 879-883
- Kelly BT, Williams RJ 3rd, Philippon MJ: Hip arthroscopy: Current indications, treatment options, and management issues. *Am J Sports Med* 31:1020-1037, 2003
- Martin H: Clinical examination of the hip. *Op Tech Orthop* 15:177-181, 2005
- Byrd J: Investigation of the symptomatic hip: Physical examination, in Byrd J (ed): *Operative Hip Arthroscopy*. New York, Thieme, 1998, pp 25-41
- Hoppenfeld S: Physical examination of the hip and pelvis, in Hoppenfeld S (ed): *Physical Examination of the Spine and Extremities*. Norwalk, Appleton & Lange, 1976, p 143
- Byrd JW: Hip arthroscopy by the supine approach. *Instr Course Lect* 55:325-336, 2006
- Ganz R, Parvizi J, Beck M, et al: Femoroacetabular impingement: A cause for osteoarthritis of the hip. *Clin Orthop Relat Res* 417:112-120, 2003
- Wenger DE, Kendell KR, Miner MR, et al: Acetabular labral tears rarely occur in the absence of bony abnormalities. *Clin Orthop Relat Res* 426:145-150, 2004
- Manaster BJ, Zakel S: Imaging of femoral acetabular impingement syndrome. *Clin Sports Med* 25:635-657, 2006
- Siebenrock KA, Kalbermatten DF, Ganz R: Effect of pelvic tilt on acetabular retroversion: A study of pelves from cadavers. *Clin Orthop Relat Res* 407:241-248, 2003
- Shindle MK, Ranawat AS, Kelly BT: Diagnosis and management of traumatic and atraumatic hip instability in the athletic patient. *Clin Sports Med* 25:309-326, ix-x, 2006
- Byrd JW, Jones KS: Diagnostic accuracy of clinical assessment, magnetic resonance imaging, magnetic resonance arthrography, and intra-articular injection in hip arthroscopy patients. *Am J Sports Med* 32: 1668-1674, 2004
- Kelly BT, Weiland DE, Schenker ML, et al: Arthroscopic labral repair in the hip: Surgical technique and review of the literature. *Arthroscopy* 21:1496-1504, 2005
- Ferguson SJ, Bryant JT, Ganz R, et al: The influence of the acetabular labrum on hip joint cartilage consolidation: A poroelastic finite element model. *J Biomech* 33:953-960, 2000
- Ferguson SJ, Bryant JT, Ganz R, et al: The acetabular labrum seal: A poroelastic finite element model. *Clin Biomech (Bristol, Avon)* 15:463-468, 2000
- Ferguson SJ, Bryant JT, Ganz R, et al: An in vitro investigation of the acetabular labral seal in hip joint mechanics. *J Biomech* 36:171-178, 2003
- Seldes RM, Tan V, Hunt J, et al: Anatomy, histologic features, and vascularity of the adult acetabular labrum. *Clin Orthop Relat Res* 382: 232-240, 2001
- Ranawat AS, Kelly BT: Function of the labrum and management of labral pathology. *Oper Tech Orthop* 15:239-246, 2005
- Adler RS, Buly R, Ambrose R, et al: Diagnostic and therapeutic use of sonography-guided iliopsoas peritendinous injections. *AJR Am J Roentgenol* 185:940-943, 2005
- Byrd JW: Hip arthroscopy. *J Am Acad Orthop Surg* 14:433-444, 2006
- Kelly BT, Shapiro GS, Digiovanni CW, et al: Vascularity of the hip labrum: a cadaveric investigation. *Arthroscopy* 21:3-11, 2005
- Ito K, Minka MA 2nd, Leunig M, et al: Femoroacetabular impingement and the cam-effect. A MRI-based quantitative anatomical study of the femoral head-neck offset. *J Bone Joint Surg Br* 83:171-176, 2001
- Lavigne M, Parvizi J, Beck M, et al: Anterior femoroacetabular impingement: Part I. Techniques of joint preserving surgery. *Clin Orthop Relat Res* 418:61-66, 2004
- Notzli HP, Wyss TF, Stoecklin CH, et al: The contour of the femoral head-neck junction as a predictor for the risk of anterior impingement. *J Bone Joint Surg Br* 84:556-560, 2002



27. Beck M, Kalhor M, Leunig M, et al: Hip morphology influences the pattern of damage to the acetabular cartilage: Femoroacetabular impingement as a cause of early osteoarthritis of the hip. *J Bone Joint Surg Br* 87:1012-1018, 2005
28. Philippon MJ, Schenker ML: Arthroscopy for the treatment of femoroacetabular impingement in the athlete. *Clin Sports Med* 25:299-308, ix, 2006
29. Shindle MK, Foo LF, Kelly BT, et al: Magnetic resonance imaging of cartilage in the athlete: current techniques and spectrum of disease. *J Bone Joint Surg Am* 88:27-46, 2006 (suppl 4)
30. Mardones RM, Gonzalez C, Chen Q, et al: Surgical treatment of femoroacetabular impingement: Evaluation of the effect of the size of the resection. *J Bone Joint Surg Am*. 87:273-279, 2005
31. Giza E, Mithofer K, Matthews H, et al: Hip fracture-dislocation in football: A report of two cases and review of the literature. *Br J Sports Med* 38:E17, 2004
32. Lamke LO: [Traumatic dislocations of the hip. Follow-up on cases from the Stockholm area]. *Acta Orthop Scand* 41:188-198, 1970
33. Mitchell DG, Steinberg ME, Dalinka MK, et al: Magnetic resonance imaging of the ischemic hip. Alterations within the osteonecrotic, viable, and reactive zones. *Clin Orthop Relat Res* 244: 60-77, 1989
34. Yang EC, Cornwall R: Initial treatment of traumatic hip dislocations in the adult. *Clin Orthop Relat Res* 377:24-31, 2000
35. Paus B: Traumatic dislocations of the hip; late results in 76 cases. *Acta Orthop Scand* 21:99-112, 1951
36. Proctor H: Dislocations of the hip joint (excluding 'central' dislocations) and their complications. *Injury* 5:1-12, 1973
37. Mullis BH, Dahners LE: Hip arthroscopy to remove loose bodies after traumatic dislocation. *J Orthop Trauma* 20:22-26, 2006
38. Moorman CT 3rd, Warren RF, Hershman EB, et al: Traumatic posterior hip subluxation in American football. *J Bone Joint Surg Am* 85-A:1190-1196, 2003
39. Philippon MJ: The role of arthroscopic thermal capsulorrhaphy in the hip. *Clin Sports Med* 20:817-829, 2001
40. Bellabarba C, Sheinkop MB, Kuo KN: Idiopathic hip instability. An unrecognized cause of coxa saltans in the adult. *Clin Orthop Relat Res* 355: 261-271, 1998