

The American Journal of Sports Medicine

<http://ajs.sagepub.com/>

Arthroscopic Iliopsoas Fractional Lengthening for Internal Snapping of the Hip: Clinical Outcomes With a Minimum 2-Year Follow-up

Youssef F. El Bitar, Christine E. Stake, Kevin F. Dunne, Itamar B. Botser and Benjamin G. Domb
Am J Sports Med published online April 25, 2014
DOI: 10.1177/0363546514531037

The online version of this article can be found at:
<http://ajs.sagepub.com/content/early/2014/04/23/0363546514531037>

Published by:



<http://www.sagepublications.com>

On behalf of:

American Orthopaedic Society for Sports Medicine



Additional services and information for *The American Journal of Sports Medicine* can be found at:

Published online April 25, 2014 in advance of the print journal.

P<P

Email Alerts: <http://ajs.sagepub.com/cgi/alerts>

Subscriptions: <http://ajs.sagepub.com/subscriptions>

Reprints: <http://www.sagepub.com/journalsReprints.nav>

Permissions: <http://www.sagepub.com/journalsPermissions.nav>

>> [OnlineFirst Version of Record](#) - Apr 25, 2014

[What is This?](#)



Arthroscopic Iliopsoas Fractional Lengthening for Internal Snapping of the Hip

Clinical Outcomes With a Minimum 2-Year Follow-up

Youssef F. El Bitar,* MD, Christine E. Stake,* MA, Kevin F. Dunne,* BS, Itamar B. Botser,* MD, and Benjamin G. Domb,*[†] MD

Investigation performed at Hinsdale Orthopaedics/American Hip Institute, Westmont, Illinois, USA

Background: Internal snapping of the hip is caused by the iliopsoas (IP) tendon sliding over the iliopectineal eminence or the femoral head. In many cases that require hip arthroscopic surgery, there is coexistent painful internal snapping. In such cases, fractional lengthening of the IP tendon has been suggested as an adjunctive procedure.

Purpose: To examine the outcomes and effectiveness of arthroscopic IP tendon fractional lengthening as a solution to coexistent internal hip snapping in patients undergoing hip arthroscopic surgery for a labral tear and/or femoroacetabular impingement.

Study Design: Case series; Level of evidence, 4.

Methods: Between June 2010 and June 2011, data were prospectively collected for all patients with internal snapping of the hip who underwent primary arthroscopic IP tendon fractional lengthening, with a minimum 2-year follow-up. All patients were interviewed by telephone with specific questions regarding the resolution or persistence of snapping. Patients were assessed preoperatively and postoperatively using the following patient-reported outcome (PRO) measures: Non-Arthritic Hip Score (NAHS), Hip Outcome Score–Activity of Daily Living (HOS-ADL) and Sport-Specific Subscale (HOS-SSS), and modified Harris Hip Score (mHHS). Pain was recorded on a visual analog scale (VAS), and satisfaction was measured on a scale from 0 to 10.

Results: A total of 55 patients were included, with all PROs showing statistically significant improvement postoperatively (NAHS: 57.6 ± 20.6 preoperatively vs 80.2 ± 19.2 at 2 years; HOS-ADL: 60.9 ± 21.4 preoperatively vs 81.8 ± 20.6 at 2 years; HOS-SSS: 43.4 ± 24.6 preoperatively vs 70.0 ± 26.7 at 2 years; and mHHS: 62.3 ± 16.4 preoperatively vs 80.5 ± 18.3 at 2 years) ($P < .001$ for all). Forty-five patients (81.8%) reported good/excellent satisfaction (≥ 7). Overall, 45 patients (81.8%) reported resolution of painful snapping. Patients who had resolution of snapping had statistically significant superior outcomes compared with those with persistent snapping using the change in the NAHS value (25.8 ± 16.1 vs 8.0 ± 22.5 , respectively; $P = .005$), change in the HOS-ADL value (23.6 ± 18.0 vs 8.5 ± 15.2 , respectively; $P = .017$), change in the HOS-SSS value (30.7 ± 26.9 vs 8.7 ± 23.6 , respectively; $P = .021$), and change in the mHHS value (23.3 ± 20.1 vs 4.4 ± 9.9 , respectively; $P = .005$).

Conclusion: A majority of patients reported resolution of painful snapping and improvement in symptoms. Nonetheless, the rate of persistence of internal snapping at a minimum 2 years postoperatively was higher than that reported in previous studies.

Keywords: iliopsoas; hip arthroscopic surgery; internal hip snapping; impingement; FAI; labrum; labral tear

Movement of the iliopsoas (IP) tendon over the iliopectineal eminence or over the femoral head is believed to produce a snapping sensation in the hip.^{10,18,21,24,31} In some patients, this occurrence creates associated pain and/or audible noise. In some instances, impingement of the IP tendon on the labrum can cause labral tears along with occasional chondral damage, resulting in painful snapping.^{2,15} Nonsurgical treatments have primarily focused on either lengthening the tendon through stretching routines or alleviating the associated pain through steroid

injections or anti-inflammatory medications.^{1,3,7,9,18,21,25} However, for some patients, surgical treatment may be necessary when nonoperative modalities fail to alleviate the symptoms. Arthroscopic release of the IP tendon has emerged as a useful minimally invasive surgical modality that is effective in treating painful internal snapping of the hip, which is generally performed in conjunction with other procedures treating labral tears and femoroacetabular impingement (FAI).^{3,15-17,22-24} Recent studies have even suggested that failure to address a taut IP tendon when performing hip arthroscopic surgery can be a contributor to less favorable outcomes.²⁰

There are a limited number of studies on internal snapping of the hip, with all being retrospective reviews of prospectively collected data, which were evaluated with

multiple different outcome scores. These studies have shown an overall high rate of success in resolving internal hip snapping through surgical methods.^{9,13,18,25} However, substantial variations in the procedures have created inconsistencies and a lack of a standardized approach to such a problem. In general, surgical methods have focused on either releasing the tendon at its attachment site on the lesser trochanter^{3,17,24} or releasing the tendinous portion of the IP muscle-tendon unit at the level of the joint, while leaving the muscle intact.^{9,16,18,23,25,34} Additionally, a few studies have examined releasing the IP tendon at the level of the femoral neck or peripheral compartment.^{23,35} Blomberg et al⁸ analyzed the cross-sectional area of the IP muscle-tendon unit at the site of arthroscopic tenotomies. They reported 3 varying tendon-to-muscle ratios present along the muscle-tendon unit, each of which has been used as a site for IP tendon release. Releasing the IP tendon is not without some drawbacks, with one of them being the loss of hip flexion strength.^{17,24,34} The procedure should ideally aim to sever enough of the tendinous portion to allow for adequate fractional lengthening, while leaving intact a maximum amount of the muscular portion to relieve snapping and minimize the risk for weakness in hip flexion.

Research examining the surgical outcomes of arthroscopic IP tendon release is somewhat scarce, and most published reports involved relatively small numbers and short-term follow-ups. All previous studies of IP tendon release focused on patients treated for internal snapping combined with FAI or labral tears.^{3,12,15-17,23,24} The purpose of this study was to examine the outcomes and effectiveness of arthroscopic IP tendon fractional lengthening at the level of the joint as a solution to internal snapping of the hip in the setting of labral tears and/or FAI surgery. To our knowledge, this study presents one of the largest cohorts to date using an arthroscopic technique with a minimum 2-year follow-up.

MATERIALS AND METHODS

Data were prospectively collected between June 2010 and June 2011 on all patients undergoing IP tendon fractional lengthening who also underwent primary hip arthroscopic surgery for labral tears and/or FAI. Data include the resolution versus persistence of painful snapping, outcome scores, as well as demographic and imaging parameters. Inclusion criteria were patients who had documented preoperative painful internal hip snapping, who underwent primary hip arthroscopic surgery with IP tendon fractional lengthening in conjunction with labral and/or FAI

treatment, and who had no significant arthritic changes in the hip (Tönnis grades 0 or 1). Painful internal snapping was documented by accurate history taking, with all patients clearly describing groin pain associated with a snapping sensation with or without an audible sound, with some being able to reproduce it in the clinic. A physical examination was also helpful in detecting some of the reported painful snapping by bringing the hip from a flexed, abducted, externally rotated position into extension with internal rotation.^{1,9,25} Painless internal hip snapping is usually a common incidental finding without clinical significance. However, this snapping can become painful, with the most common cause of painful internal snapping being related to lesions of the IP tendon.^{9,14} None of the patients necessitated ultrasound scans or injections for diagnostic or therapeutic purposes because all patients were diagnosed with a labral tear and/or FAI clinically in addition to a radiographic assessment with plain radiographs and magnetic resonance arthrography (MRA).

Included patients had a minimum 2-year follow-up and received the following 4 patient-reported outcome (PRO) scores preoperatively and at 2-year follow-up: the Non-Arthritic Hip Score (NAHS), the Hip Outcome Score–Activity of Daily Living (HOS-ADL) and Sport-Specific Subscale (HOS-SSS), and the modified Harris Hip Score (mHHS). Patients with previous hip conditions such as fractures, Legg-Calve-Perthes disease, slipped capital femoral epiphysis, osteonecrosis of the femoral head, and hip dysplasia were excluded from the study. Patients who refused to participate in the follow-up were also excluded as well as patients with missing or suboptimal preoperative radiographs.

Patient demographics including age, sex, and body mass index (BMI) were reported in this study. Patients were considered to have a cam-type deformity when the α angle measured $>50^\circ$ in the radiographic Dunn view.^{5,6,19} A pincer-type deformity was determined by the presence of at least 1 of the following radiographic measurements in the anteroposterior (AP) pelvis view: crossover sign,^{26,32} ischial spine sign,²⁷ coxa profunda,³³ protrusio acetabuli,⁴ and lateral center edge angle (LCEA) $>40^\circ$.²⁸ The LCEA was measured in the supine AP pelvis view as well as the Tönnis grade. The anterior center edge angle (ACEA) was measured in the standing false-profile view of the hip. Hip dysplasia was diagnosed when the Wiberg LCEA was $<20^\circ$ and/or the Lequesne ACEA was $<20^\circ$. Femoral anteversion was measured on MRA using a line tangent to the posterior femoral condyles in the axial view of the knee and the line along the femoral neck axis in the axial view of the hip. All concomitant procedures performed during hip arthroscopic surgery were also reported including

[†]Address correspondence to Benjamin G. Domb, MD, Hinsdale Orthopaedics/American Hip Institute, 1010 Executive Court, Suite 250, Westmont, IL 60559, USA (e-mail: DrDomb@AmericanHipInstitute.org).

*Hinsdale Orthopaedics/American Hip Institute, Westmont, Illinois, USA.

One or more of the authors has declared the following potential conflict of interest or source of funding: This study was funded by the American Hip Institute, which received funding from Arthrex Inc (February 2012), MAKO Surgical Corp (February 2012), Pacira (pending), ATI (August 2013), and Breg (June 2012). B.G.D. receives research support from Arthrex Inc, MAKO Surgical Corp, MedWest, Breg, ATI, American Hip Institute, and Pacira; provides consulting services for Arthrex Inc, Pacira, and MAKO Surgical Corp; receives royalties from DJO Global and Orthomerica; is a board member of the American Hip Institute, American Orthopedic Foundation (February 2012), and AANA Learning Center Committee; holds stock in Stryker (September 2013) and MAKO Surgical Corp (July 2013); and has patent applications pending related to the arthroscopic labral reconstruction technique, kit, and hip brace (in process).

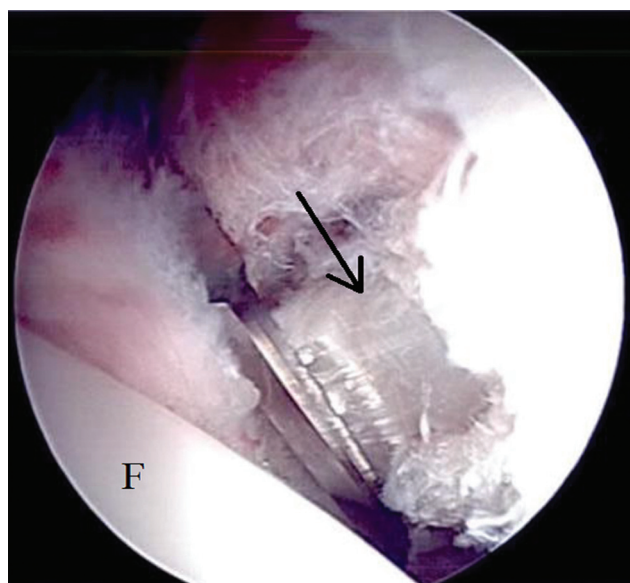


Figure 1. Arthroscopic view of the iliopsoas tendon that is well visualized from the central compartment. The arrow depicts the taut and intact iliopsoas tendon. F, femoral head.

labral treatment, acetabuloplasty, femoroplasty, capsule release or repair, and acetabular or femoral head microfracture. The visual analog scale (VAS) was used to assess pain preoperatively and at follow-up. Patient satisfaction was also reported on a scale from 0 to 10, with 0 being highly dissatisfied and 10 being highly satisfied. The resolution or persistence of painful internal snapping of the hip was recorded using telephone interviews with the patients. When the snapping persisted, it was graded according to frequency—A = rare (≤ 1 time/month), B = occasional (2-5 times/month), C = often (> 5 times/month to < 5 times/week), and D = frequent (≥ 5 times/week or daily)—and whether it was painful or not. Internal comparison between the patients who had resolution of painful internal hip snapping and those who had persistence of painful snapping was also performed.

Short- and long-term complications were recorded as well as endpoints such as revision hip arthroscopic surgery for any reason and conversion to total hip arthroplasty (THA) or resurfacing arthroplasty. Investigational review board approval was obtained before the initiation of this study.

Surgical Technique

All patients who underwent hip arthroscopic surgery had failed nonoperative measures to treat their hip pain for at least 3 months. Nonoperative treatment included a modification of activities, physical therapy, and oral nonsteroidal anti-inflammatory drugs. All arthroscopic procedures were performed by the senior surgeon (B.G.D.) with the patient in the supine position. Diagnostic arthroscopic surgery was performed after capsulotomy to check for labral tears, loose bodies, synovitis, ligamentum teres tears, and other pathological lesions. Chondral damage to the

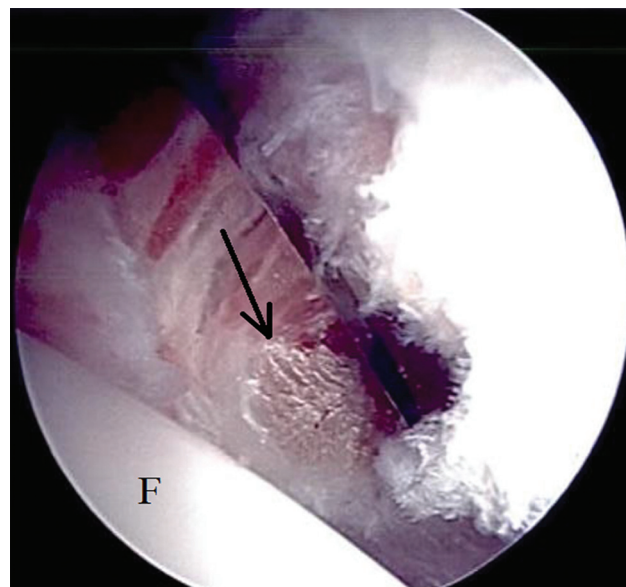


Figure 2. Arthroscopic view of iliopsoas tendon fractional lengthening using a beaver blade. The tendinous portion of the iliopsoas was released, maintaining the remainder of the muscular portion intact. The arrow depicts the released distal stump of the iliopsoas tendon. F, femoral head.

acetabulum was graded using the Acetabular Labrum Articular Disruption (ALAD) classification system,¹¹ with class 1 being softening of acetabular cartilage, class 2 being early peel back of cartilage with a positive wave sign, class 3 being a large chondral flap, and class 4 being a complete loss of cartilage. The Outerbridge classification was used to grade chondral damage to the femoral head.³⁰ If needed, cam and pincer lesions were addressed under fluoroscopic guidance with acetabuloplasty and femoroplasty, respectively. Labral tears were repaired when possible; otherwise, they were either debrided or reconstructed. Any additional therapeutic procedures were performed as needed before or after IP tendon fractional lengthening.

With traction still applied, IP tendon fractional lengthening was performed through the central compartment at the level of the joint line, where the IP is approximately 50% tendon and 50% muscle. To expose the IP tendon at the joint level, medial extension of capsulotomy was performed. Next, using a shaver, the medial and lateral borders of the IP tendon were exposed. A beaver blade was then used to transversely incise the IP tendon, while leaving the muscular portion intact (Figures 1 and 2). This resulted in recession-type fractional lengthening of the IP tendon. We adopted this approach because of the ease of access to the IP tendon using the intracapsular approach while performing hip arthroscopic surgery, in addition to preserving the muscular portion of the IP at the level of the joint, which would theoretically preserve hip flexion strength. The capsule was repaired at the end of the procedure when indicated (see the online Video Supplement).

Postoperative rehabilitation for patients undergoing arthroscopic IP tendon fractional lengthening followed the

same protocol as that for all the patients undergoing hip arthroscopic surgery. The goals were to protect the repaired tissues, restore range of motion, prevent muscular inhibition or gait abnormalities, and diminish any pain or inflammation. This was done by first placing patients in a hip brace (DJO Global, Vista, California, USA) for a minimum of 2 weeks after surgery. Patients were restricted to 20 lb of foot-flat weightbearing activity for 2 to 4 weeks. The protocol included continuous passive motion for the first 6 weeks. Starting the first day after surgery, patients began stationary biking with a high seat (to avoid pinching) for 2 to 4 hours a day. A slow progression to full strength and activity occurred over a 3- to 4-month period.

Statistical Analysis

SPSS Statistics v 20 (IBM Corp, Armonk, New York, USA) was used to perform all the statistical analyses in this study. The mean ± standard deviation and range for age, BMI, traction time, follow-up time, α angle, LCEA, ACEA, femoral anteversion, and preoperative and last follow-up PRO and VAS scores were calculated. The paired Student *t* test was used to compare the preoperative values to the last follow-up values of all the PROs. The independent Student *t* test was used for internal comparison of the means of both groups (painful snapping resolved vs painful snapping persisted) in regards to age, BMI, α angle, LCEA, ACEA, traction time, baseline preoperative PRO scores, last follow-up PRO scores, and amount of change in the PRO scores (ΔPROs). The Fisher exact test was used to compare sex, Tönnis grade, pincer lesion, cam lesion, labral treatment (debridement vs repair/reconstruction), acetabuloplasty, femoroplasty, microfracture, capsule procedure (repair vs release), patient satisfaction, and subsequent revisions in both groups. A *P* value <.05 was considered to be statistically significant for all the statistical analyses.

RESULTS

Of 408 hip arthroscopic procedures performed during the study time period, 75 hips underwent IP tendon fractional lengthening. Nine cases were revision surgeries, and those were excluded, resulting in 66 cases that met the inclusion criteria. All 66 patients had preoperative painful snapping of the hip and underwent arthroscopic IP tendon fractional lengthening in conjunction with labral and/or FAI treatment. Of the 66 hips eligible for inclusion, 55 (83.3%) were available for follow-up at a minimum of 2 years.

The patient population consisted of 17 male and 38 female participants, with a mean age of 28.2 ± 10.5 years (range, 14.9-51.5 years), mean BMI of 23.6 ± 4.6 kg/m² (range, 18.2-39.9 kg/m²), and mean follow-up time of 2.3 ± 0.3 years (range, 2.0-3.0 years). All patients had no or minimal arthritic changes in the hip, with 44 (80.0%) having Tönnis grade 0, 11 (20.0%) having Tönnis grade 1, and none having Tönnis grade 2 or 3 osteoarthritis. The mean α angle was 53.2° ± 8.1° (range 39°-70°). The mean LCEA was 30.7° ± 4.0° (range, 25°-39°), and the mean ACEA was 30.7° ± 7.1° (range, 20°-48°). Femoral version

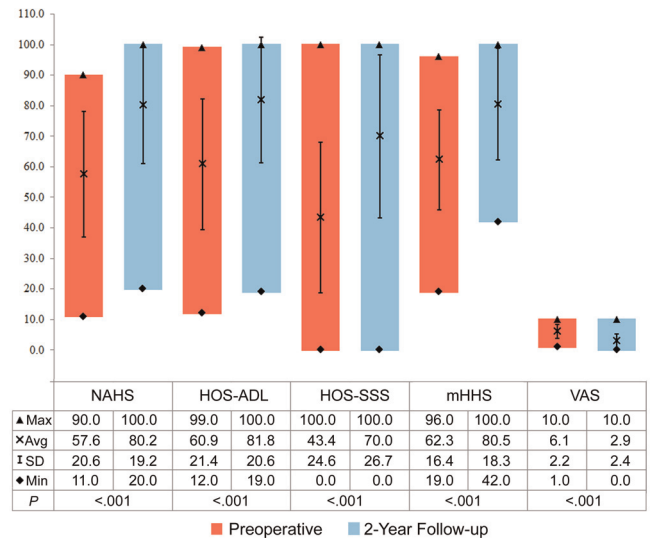


Figure 3. Total cohort outcome scores. HOS-ADL, Hip Outcome Score–Activity of Daily Living; HOS-SSS, Hip Outcome Score–Sport–Specific Subscale; mHHS, modified Harris Hip Score; NAHS, Non-Arthritic Hip Score; VAS, visual analog scale for pain.

measurements were available for 35 patients (63.6%), and the mean was 5.7° ± 6.6° (range, -18° to 16°). All patients were found to have labral tears on preoperative MRA. All the tears were found in the anterosuperior segment of the acetabulum with variable sizes. There were 42 acetabuloplasties (76.4%) for pincer-type impingement and 29 femoroplasties (52.7%) for cam-type impingement. Labral debridement was performed in 11 cases (20.0%), repair in 38 cases (69.1%), and reconstruction in 6 cases (10.9%). Acetabular microfracture was performed in 9 cases (16.4%). The capsule was released in 12 cases (21.8%) and repaired in 43 cases (78.2%). The mean traction time was 59.0 ± 21.9 minutes (range, 18-130 minutes).

The outcome was considered favorable when painful snapping resolved and considered unfavorable when painful snapping persisted. Painful snapping persisted in 10 patients (18.2%). Snapping grades were A in 1 patient with no pain, B in 5 patients (4 associated with pain), C in 2 patients (1 associated with pain), and D in 6 patients (5 associated with pain). All 4 PROs and the VAS showed statistically significant improvement at a minimum 2-year follow-up with *P* values <.001 in all (Figure 3). Subjective patient satisfaction showed 81.8% good to excellent results (45 patients with satisfaction ≥7).

Comparing the patients who had resolution of painful snapping to those who had persistence of painful snapping showed no statistically significant difference in the baseline demographic and imaging parameters (Table 1), no difference in the surgical parameters (Table 1), and no difference in the baseline preoperative PRO or VAS scores (Figure 4). Patients with resolution of painful snapping showed statistically significant improvement in all 4 PROs and the VAS (Table 2), while patients with

TABLE 1
Demographic, Imaging, and Surgical Data and Patient Satisfaction for the
Resolution of Painful Snapping Group Versus the Persistence of Painful Snapping Group^a

	Resolution of Painful Snapping	Persistence of Painful Snapping	P Value
Age, y	28.1 ± 11.1 (14.9-51.5)	28.9 ± 7.7 (16.8-41.9)	.822
BMI, kg/m ²	23.5 ± 4.8 (18.2-39.9)	23.8 ± 3.9 (19.5-33.0)	.850
Sex, male/female, n	16/29	1/9	.148
Tönnis grade 0/grade 1, grades 2-4, n	35/10/0	9/1/0	.667
α angle, deg	53.4 ± 8.1 (39.0-70.0)	52.5 ± 8.1 (39.0-65.0)	.764
LCEA, deg	31.1 ± 4.2 (25.0-39.0)	29.0 ± 2.9 (25.0-35.0)	.131
ACEA, deg	31.1 ± 7.4 (20.0-48.0)	30.6 ± 6.1 (22.0-43.0)	.833
Traction time, min	61.5 ± 22.5 (23.0-130.0)	47.9 ± 15.1 (18.0-75.0)	.075
Pincer, yes/no, n	36/9	6/4	.223
Acetabuloplasty, yes/no, n	36/9	6/4	.223
Cam, yes/no, n	26/19	3/7	.164
Femoroplasty, yes/no, n	26/19	3/7	.164
Labrum, debridement/repair or reconstruction, n	8/37	3/7	.400
Microfracture, yes/no, n	8/37	1/9	1.000
Capsule, release/repair, n	10/35	2/8	1.000
Revision, yes/no, n	4/41	4/6	.029
Patient satisfaction, ≥7/<7, n	42/3	3/7	<.001

^aValues are expressed as mean ± standard deviation (range) unless otherwise indicated. ACEA, anterior center edge angle; BMI, body mass index; LCEA, lateral center edge angle.

TABLE 2
Change in Outcome Scores in Both the Resolution of Painful Snapping Group
and the Persistence of Painful Snapping Group^a

	Resolution of Painful Snapping			Persistence of Painful Snapping		
	Preoperatively	2-Year Follow-up	P Value	Preoperatively	2-Year Follow-up	P Value
NAHS	58.2 ± 20.3 (16-90)	84.1 ± 16.5 (39-100)	<.001	54.8 ± 22.8 (11-90)	62.8 ± 21.5 (20-89)	.291
HOS-ADL	61.9 ± 22.0 (12-99)	85.5 ± 18.4 (29-100)	<.001	56.5 ± 18.7 (24-81)	65.0 ± 22.6 (19-93)	.109
HOS-SSS	43.8 ± 25.9 (0-100)	74.4 ± 24.4 (11-100)	<.001	41.5 ± 19.0 (9-67)	50.2 ± 28.7 (0-100)	.272
mHHS	63.3 ± 17.5 (19-96)	84.6 ± 16.5 (42-100)	<.001	57.6 ± 10.1 (42-74)	62.0 ± 14.4 (45-85)	.197
VAS	6.0 ± 2.2 (1-10)	2.4 ± 2.1 (0-8)	<.001	6.6 ± 2.1 (3-10)	4.8 ± 3.0 (0-10)	.105

^aValues are expressed as mean ± standard deviation (range). HOS-ADL, Hip Outcome Score–Activity of Daily Living; HOS-SSS, Hip Outcome Score–Sport-Specific Subscale; mHHS, modified Harris Hip Score; NAHS, Non-Arthritic Hip Score; VAS, visual analog scale for pain.

persistence of painful snapping did not have any statistically significant improvement in any of the 4 PROs or the VAS (Table 2). Comparing the change in the PRO scores (from preoperative to follow-up) showed a statistically significant difference in all 4 PROs in favor of the group with resolution of painful snapping (Figure 5). Patient satisfaction was significantly better in those with resolution of painful snapping (42 patients with satisfaction ≥7 and 3 with satisfaction <7) compared with those with persistence of painful snapping (3 patients with satisfaction ≥7 and 7 with satisfaction <7) ($P < .001$) (Table 1).

Of the 55 hip arthroscopic procedures in this study, 8 hips (14.5%) underwent subsequent revision surgery: none of them for snapping, 6 for retearing of the labrum, 1 for stiffness, and 1 for removal of heterotopic ossification. Four of the revisions had resolution of painful snapping, while 4 had persistence of painful snapping, and the difference was statistically significant ($P = .029$). One of the 8

patients who underwent revision hip arthroscopic surgery went on to undergo THA 2.5 years after the primary hip arthroscopic procedure. One patient had a superficial wound infection that was adequately treated with oral antibiotics, and 1 female patient reported numbness in the genitalia that resolved at 3 months postoperatively.

DISCUSSION

The current study examined 55 cases of arthroscopic IP tendon fractional lengthening for painful internal hip snapping at the level of the joint, where the IP is approximately 50% tendon and 50% muscle. With a minimum follow-up of 2 years, all PRO scores showed statistically significant improvement, with patient satisfaction showing 81.8% (45/55) good to excellent results. Painful snapping resolved in 81.8% (45/55) of the cases, with all PROs

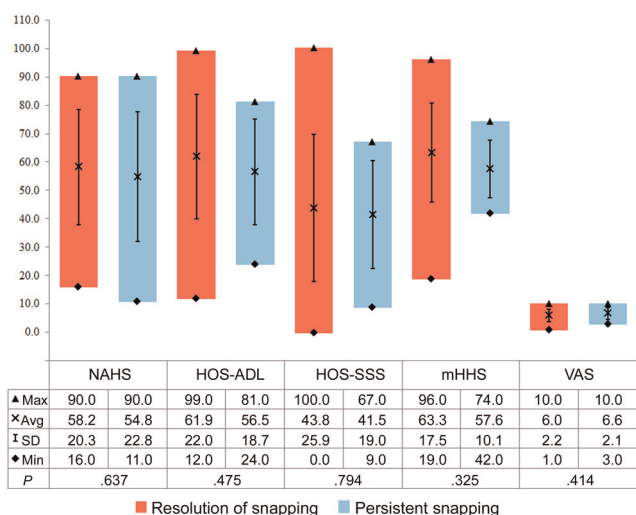


Figure 4. Comparison of baseline preoperative patient-reported outcomes between the resolution of painful snapping group and the persistence of painful snapping group.

showing statistically significant improvement at the last follow-up. Fabricant et al¹⁶ published the largest arthroscopic series of 67 cases of IP tendon lengthening for painful snapping with or without labral and FAI surgery. All patients showed improvement in the mHHS value at a minimum 6-month follow-up (up to 24 months). Patients with high femoral version ($>25^\circ$) had worse postoperative mHHS values than the ones with low/normal version ($\leq 25^\circ$).¹⁶ However, the study did not report on the resolution or persistence of painful snapping. In the current study, 35 patients (63.6%) had available femoral version measurements, with none having an angle of $>25^\circ$. Only 4 of 10 patients with persistent painful snapping had available measurements, limiting our ability to draw conclusions.

Ten patients (18.2%) had persistent painful snapping at the last follow-up, with 5 of those having frequent symptoms (≥ 5 times/week or daily), with no statistically significant improvement detected in all the PROs at the last follow-up. All variables including demographics, radiographic data, and surgical procedures (type of labral treatment, acetabuloplasty, femoroplasty, microfracture, and type of capsule treatment) showed no statistically significant difference between patients who had resolution of painful snapping and those who had persistence of painful snapping (Table 1). Satisfaction was significantly better in the resolution of painful snapping group ($P < .001$) (Table 1). Multiple causes can be related to the persistence of painful snapping including the presence of multiple tendon slips not detected on MRA or intraoperatively, formation of scar tissue at the tenotomy site or in the capsule, tightness of the muscular portion of the IP, and other subtle concomitant injuries that might have been missed or deemed normal intraoperatively. In addition, the number of patients might not have provided enough power to detect statistical differences in preoperative and intraoperative variables between both groups.

The current literature on hip arthroscopic surgery shows varying degrees of success in treating painful internal

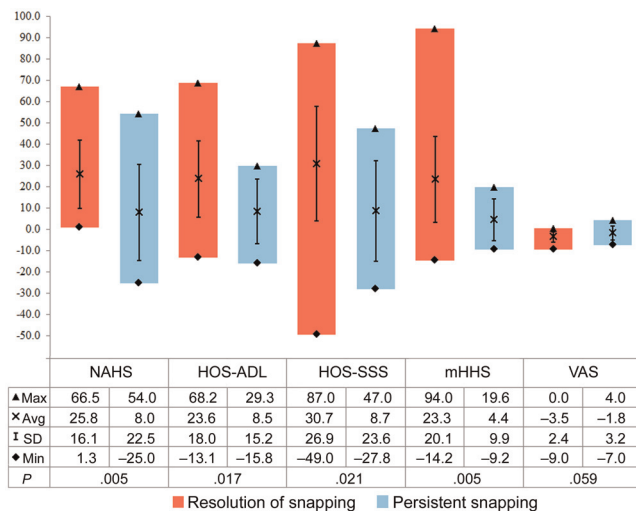


Figure 5. Comparison of improvement in patient-reported outcomes between the resolution of painful snapping group and the persistence of painful snapping group.

snapping. Contreras et al¹² performed a release in 7 patients at the level of the joint under traction, with a 2-year follow-up. There was a significant decrease in the pain level and increase in the mHHS value. However, this study had a small cohort, and only 1 patient associated pain with snapping preoperatively. Domb et al¹⁵ reported on IP tendon fractional lengthening at the level of the joint in 25 hips with a minimum 1-year follow-up. Twenty-two patients reported improved physical activity postoperatively; however, only 8 patients had available preoperative and follow-up PROs showing statistically significant improvement in their scores.¹⁵ Anderson and Keene³ reported on 15 athletes who underwent IP release at the level of the lesser trochanter, with a minimum 1-year follow-up. The mHHS value showed significant improvement at the last follow-up with resolution of internal snapping and intact hip flexion power; however, 6 patients still had pain.³ Similarly, Flannum et al¹⁷ reported on 6 patients who underwent IP release at the level of the lesser trochanter. The mHHS value showed significant improvement, with 2 patients reporting persistent pain at the last follow-up.¹⁷

Open surgical release of the IP tendon has been also described in the literature with varying degrees of success. Hoskins et al²¹ used an open ilioinguinal approach in 92 hips, which is the largest cohort reported in the literature. Patients were diagnosed clinically and at follow-up by telephone, with a mean follow-up of 5.4 years.²¹ Six patients had persistent pain, 20 patients had recurrent or persistent internal snapping, and patient satisfaction was 89%. Taylor and Clarke³⁴ reported on 16 hips diagnosed clinically, with a mean follow-up of 17 months. They performed a release using a 5-cm incision, 2.5 cm below the inguinal skin crease and centered over the palpable border of the adductors.³⁴ Six hips had recurrent hip clicking, and 3 were still experiencing pain. Gruen et al¹⁸ used the ilioinguinal approach in 12 hips, with a mean follow-up of 3 years. The tendon was severed within the muscle belly,

leaving the muscular portion intact as well as the tendinous point of insertion onto the lesser trochanter. There was no recurrence of snapping; however, 2 hips were still painful, and 5 hips had subjective weakness in hip flexion. Jacobson and Allen²⁵ reported on 20 patients at a mean of 25 months' follow-up, with 6 patients having a recurrence. Dobbs et al¹³ reported on 11 hips at a mean of 4 years' follow-up, with 1 patient with a recurrence.

In general, internal snapping of the hip is rarely an isolated indication for surgery. When snapping is associated with pain, IP release or fractional lengthening is usually warranted and usually performed in association with other arthroscopic procedures dealing with labral and chondral damage or FAI. Several studies reported on the release of the IP tendon as a treatment for internal snapping. Some of those diagnosed snapping based on history taking and a clinical examination,^{21,23,24,34} while others confirmed their diagnosis using ultrasound-guided injections into the IP in either all the cases^{3,16,17} or some of them.^{15,18} In the current study, the diagnosis of painful internal hip snapping was made confidently using history taking and a clinical examination, without resorting to further investigation using ultrasound-guided injections.

Leaving the muscular portion of the IP intact should theoretically preserve hip flexion strength. Ilizaliturri et al²⁴ described an endoscopic technique to fully release the IP tendon at the lesser trochanter in 7 cases, with a mean follow-up of 21 months. The symptoms resolved in all cases, and outcome scores improved despite no statistical analysis or *P* value reported. In addition, all patients experienced a loss of flexion strength at least temporarily. Other authors reported no weakness in hip flexion using the arthroscopic technique.^{3,17,23} Using the open technique, some authors reported the occurrence of weakness in hip flexion in some of their cases.^{18,21,34} Blomberg et al⁸ described the anatomy of 3 different points of release: at the level of the labrum, the femoral neck, and the lesser trochanter. They suggested that a partial release could be performed at the tendon's insertion onto the lesser trochanter without releasing the entire muscular tendon unit, as this level is composed of approximately 60% tendon and 40% muscle. They also suggested that a transcapsular release performed at the level of the femoral neck preserved similar percentages of the muscle-tendon unit. This theory was supported by the findings of Ilizaliturri et al,²³ which demonstrated no difference in clinical outcomes in patients undergoing IP release at these 2 distinct release levels.

This study is not without some limitations. One limitation is the modest number of patients and the relatively short-term follow-up. Another limitation, which is common to all other previous publications, is the heterogeneity of this cohort in dealing with other concomitant injuries present inside the hip joint such as labral tears and cam- and pincer-type impingement lesions. Another limitation is the lack of a detailed anatomic description of the IP tendon and its proximity to the labral tear on preoperative MRA. Measurements of hip flexion strength were not available preoperatively or postoperatively and should be a subject of further study.

The current study had several advantages. The period of follow-up of a minimum 2 years is the longest for an

arthroscopic technique reported in the literature, with an 83.3% follow-up rate. The technique used was consistent throughout the patient cohort, and it was possible to compare patients with resolution of painful snapping to those with persistence of painful snapping. The PRO scores that were used were designed specifically to detect outcomes in active patients with nonarthritic hips.^{16,29} The outcomes and satisfaction results were good to excellent overall. This patient cohort had a slightly higher rate of persistence of painful snapping compared with previous studies possibly because of the longer follow-up or because patients were specifically contacted and asked directly if they still had snapping. Other studies may not have done so and therefore may have been less sensitive at detecting persistent painful snapping.

CONCLUSION

A majority of patients reported resolution of painful snapping and improvement in symptoms. Nonetheless, the rate of persistence of painful internal snapping at a minimum 2 years postoperatively was somewhat higher than that reported in previous studies. Overall clinical outcomes were favorable, and we continue to make use of IP fractional lengthening mostly as an adjunctive procedure for patients with painful internal snapping who undergo arthroscopic surgery for labral tears and/or FAI.

ACKNOWLEDGMENT

The authors acknowledge Nathan A. Finch, MA, for his contributions to this study.

A Video Supplement for this article is available in the online version or at <http://ajsm.sagepub.com/supplemental>.

REFERENCES

- Allen WC, Cope R. Coxa saltans: the snapping hip revisited. *J Am Acad Orthop Surg*. 1995;3(5):303-308.
- Alpert JM, Kozanek M, Li G, Kelly BT, Asnis PD. Cross-sectional analysis of the iliopsoas tendon and its relationship to the acetabular labrum: an anatomic study. *Am J Sports Med*. 2009;37(8):1594-1598.
- Anderson SA, Keene JS. Results of arthroscopic iliopsoas tendon release in competitive and recreational athletes. *Am J Sports Med*. 2008;36(12):2363-2371.
- Armbuster TG, Guerra J Jr, Resnick D, et al. The adult hip: an anatomic study. Part I: the bony landmarks. *Radiology*. 1978;128(1):1-10.
- Barton C, Salineros MJ, Rakhra KS, Beaulé PE. Validity of the alpha angle measurement on plain radiographs in the evaluation of cam-type femoroacetabular impingement. *Clin Orthop Relat Res*. 2011;469(2):464-469.
- Beaulé PE, Zaragoza E, Motamedi K, Copelan N, Dorey FJ. Three-dimensional computed tomography of the hip in the assessment of femoroacetabular impingement. *J Orthop Res*. 2005;23(6):1286-1292.
- Blankenbaker DG, De Smet AA, Keene JS. Sonography of the iliopsoas tendon and injection of the iliopsoas bursa for diagnosis and management of the painful snapping hip. *Skeletal Radiol*. 2006;35(8):565-571.

8. Blomberg JR, Zellner BS, Keene JS. Cross-sectional analysis of iliopsoas muscle-tendon units at the sites of arthroscopic tenotomies: an anatomic study. *Am J Sports Med.* 2011;39(Suppl):58S-63S.
9. Byrd JW. Evaluation and management of the snapping iliopsoas tendon. *Instr Course Lect.* 2006;55:347-355.
10. Byrd JW. Hip arthroscopy utilizing the supine position. *Arthroscopy.* 1994;10(3):275-280.
11. Callaghan JJ, Rosenberg AG, Rubash HE. *The Adult Hip.* 2nd ed. Philadelphia: Lippincott Williams & Wilkins; 2007.
12. Contreras ME, Dani WS, Endges WK, De Araujo LC, Berral FJ. Arthroscopic treatment of the snapping iliopsoas tendon through the central compartment of the hip: a pilot study. *J Bone Joint Surg Br.* 2010;92(6):777-780.
13. Dobbs MB, Gordon JE, Luhmann SJ, Szymanski DA, Schoenecker PL. Surgical correction of the snapping iliopsoas tendon in adolescents. *J Bone Joint Surg Am.* 2002;84(3):420-424.
14. Domb BG, Brooks AG, Byrd JW. Clinical examination of the hip joint in athletes. *J Sport Rehabil.* 2009;18(1):3-23.
15. Domb BG, Shindle MK, McArthur B, Voos JE, Magennis EM, Kelly BT. Iliopsoas impingement: a newly identified cause of labral pathology in the hip. *HSS J.* 2011;7(2):145-150.
16. Fabricant PD, Bedi A, De La Torre K, Kelly BT. Clinical outcomes after arthroscopic psoas lengthening: the effect of femoral version. *Arthroscopy.* 2012;28(7):965-971.
17. Flanum ME, Keene JS, Blankenbaker DG, Desmet AA. Arthroscopic treatment of the painful "internal" snapping hip: results of a new endoscopic technique and imaging protocol. *Am J Sports Med.* 2007;35(5):770-779.
18. Gruen GS, Scioscia TN, Lowenstein JE. The surgical treatment of internal snapping hip. *Am J Sports Med.* 2002;30(4):607-613.
19. Hack K, Di Primio G, Rakhra K, Beaulieu PE. Prevalence of cam-type femoroacetabular impingement morphology in asymptomatic volunteers. *J Bone Joint Surg Am.* 2010;92(14):2436-2444.
20. Heyworth BE, Shindle MK, Voos JE, Rudzki JR, Kelly BT. Radiologic and intraoperative findings in revision hip arthroscopy. *Arthroscopy.* 2007;23(12):1295-1302.
21. Hoskins JS, Burd TA, Allen WC. Surgical correction of internal coxa saltans: a 20-year consecutive study. *Am J Sports Med.* 2004;32(4):998-1001.
22. Ilizaliturri VM Jr, Camacho-Galindo J. Endoscopic treatment of snapping hips, iliotibial band, and iliopsoas tendon. *Sports Med Arthrosc.* 2010;18(2):120-127.
23. Ilizaliturri VM Jr, Chaidez C, Villegas P, Briseno A, Camacho-Galindo J. Prospective randomized study of 2 different techniques for endoscopic iliopsoas tendon release in the treatment of internal snapping hip syndrome. *Arthroscopy.* 2009;25(2):159-163.
24. Ilizaliturri VM Jr, Villalobos FE Jr, Chaidez PA, Valero FS, Aguilera JM. Internal snapping hip syndrome: treatment by endoscopic release of the iliopsoas tendon. *Arthroscopy.* 2005;21(11):1375-1380.
25. Jacobson T, Allen WC. Surgical correction of the snapping iliopsoas tendon. *Am J Sports Med.* 1990;18(5):470-474.
26. Jamali AA, Mladenov K, Meyer DC, et al. Anteroposterior pelvic radiographs to assess acetabular retroversion: high validity of the "cross-over-sign." *J Orthop Res.* 2007;25(6):758-765.
27. Kalberer F, Sierra RJ, Madan SS, Ganz R, Leunig M. Ischial spine projection into the pelvis: a new sign for acetabular retroversion. *Clin Orthop Relat Res.* 2008;466(3):677-683.
28. Kutty S, Schneider P, Faris P, et al. Reliability and predictability of the centre-edge angle in the assessment of pincer femoroacetabular impingement. *Int Orthop.* 2012;36(3):505-510.
29. Lodhia P, Slobogean GP, Noonan VK, Gilbert MK. Patient-reported outcome instruments for femoroacetabular impingement and hip labral pathology: a systematic review of the clinimetric evidence. *Arthroscopy.* 2011;27(2):279-286.
30. Outerbridge RE. The etiology of chondromalacia patellae. *J Bone Joint Surg Br.* 1961;43:752-757.
31. Polster JM, Elgabaly M, Lee H, Klika A, Drake R, Barsoum W. MRI and gross anatomy of the iliopsoas tendon complex. *Skeletal Radiol.* 2008;37(1):55-58.
32. Reynolds D, Lucas J, Klaue K. Retroversion of the acetabulum: a cause of hip pain. *J Bone Joint Surg Br.* 1999;81(2):281-288.
33. Ruelle M, Dubois JL. [The protrusive malformation and its arthrosic complication: I. Radiological and clinical symptoms: etiopathogenesis]. *Rev Rhum Mal Osteoartic.* 1962;29:476-489.
34. Taylor GR, Clarke NM. Surgical release of the 'snapping iliopsoas tendon.' *J Bone Joint Surg Br.* 1995;77(6):881-883.
35. Wettstein M, Jung J, Dienst M. Arthroscopic psoas tenotomy. *Arthroscopy.* 2006;22(8):907.e1-907.e4.

For reprints and permission queries, please visit SAGE's Web site at <http://www.sagepub.com/journalsPermissions.nav>