

# Selective Component Retainment in the Treatment of Chronic Periprosthetic Infection After Total Hip Arthroplasty: A Systematic Review

Philip J. Rosinsky, MD  
 Arie Greenberg, MD  
 Hagay Amster-Kahn, MD  
 Pierre Campenfeldt, MD  
 Benjamin G. Domb, MD  
 Yona Kosashvili, MD

From the Kaplan Medical Center (Dr. Rosinsky, Dr. Greenberg, Dr. Amster-Kahn, and Dr. Kosashvili), Rehovot, Israel, the American Hip Institute (Dr. Rosinsky and Dr. Domb), Des Plaines, IL, and the Karolinska Institutet (Dr. Campenfeldt), Solna, Sweden.

Correspondence to Dr. Rosinsky:  
 Philip.rosinsky@americanhipinstitute.org

Supplemental digital content is available for this article. Direct URL citation appears in the printed text and is provided in the HTML and PDF versions of this article on the journal's Web site ([www.jaaos.org](http://www.jaaos.org)).

*J Am Acad Orthop Surg* 2019;00:1-8

DOI: 10.5435/JAAOS-D-19-00457

Copyright 2019 by the American Academy of Orthopaedic Surgeons.

## Abstract

**Introduction:** Chronic infections after a total hip arthroplasty (THA) are a devastating complication and are usually treated by a complete revision of components. Selective revision, with preservation of well-fixed components, has been previously reported. We did a systematic review to report on success rates of selective revision in chronic infections after THA.

**Methods:** PubMed, Web of Science, and the Cochrane Database were systematically searched for studies reporting on partial-retaining revision for chronically infected THA. These were reviewed to determine success rates based on component revised, as well as infectious organism.

**Results:** Nine studies reported on 134 patients. The majority of the patients underwent femoral-retaining procedures (118), and the rest of the patients underwent acetabular-retaining procedures (16). Average follow-up was 60.56 months, and the success rates were 80% for femoral revision, 90.43% for acetabular revision, and overall success rate was 89.41%.

**Discussion:** In select patients, retainment of well-fixed components in chronically infected THA may be considered. Although reported success rates are high, and comparable with complete revision arthroplasty in cases of chronic infections, the quality of the studies included is poor. The studies lacked sufficient internal validity, sample size, methodological consistency, and standardization of protocols and outcomes.

**Level of Evidence:** Systematic review of level IV studies

In the United States, the annual volume of primary total hip arthroplasties (THAs) has increased over the past 20 years reaching close to 700,000 in 2014. The numbers are in a constant rise, and it is expected that by 2030, close to 1,000,000 primary cases of THA will be performed a year.<sup>1</sup> Approximately 50,000 revision THAs are performed annually in

the United States, and this is expected to double by 2026, which is attributed to a younger cohort and higher activity level in the index procedure.<sup>2</sup> Similar trends have been shown in Europe as well.<sup>3,4</sup>

One of the most devastating complications of THA is infection, leading to higher morbidity, prolonged hospitalization, worse patient-

reported outcomes, and higher mortality.<sup>5–7</sup> A registry-based study of THAs done between 2001 and 2009 found an infection rate of 1.99% in 2001, increasing to 2.18% by 2009, with a year-to-year increase throughout the study period. By 2020, an expected 16,584 annual cases of infected THA are expected, with these creating a heavy economic burden on the medical system.<sup>8</sup>

Management of periprosthetic joint infection (PJI) is multifaceted and complicated. Oftentimes, the diagnosis of chronic infection is delayed, while management of this condition is complicated by prolonged hospitalization and antibiotic treatment and often multiple surgical interventions. Tsukayama et al<sup>9</sup> classified infected THA according to chronicity into acute (early postoperative), chronic (late postoperative), acute hematogenous, and incidental cultures obtained during revision surgery. In acute and acute hematogenous infections, several studies have shown the viability of prosthesis retention while doing débridement, antibiotic treatment, and implant retention (DAIR).<sup>10</sup> By contrast, in chronic cases, the benchmark for treatment has traditionally been a two-stage complete revision, with prosthesis extraction, thorough débridement and lavage, antibiotic impregnated spacer implantation, and finally, after a period of antibi-

otic treatment, a second stage of new prosthesis implantation.<sup>11</sup> Systematic reviews and meta-analyses have reported a 90% success rate in infection eradication using a two-stage approach.<sup>12</sup> Over recent years, the option of single-stage revision in treatment of infected THAs has been developed with success rates approaching and exceeding the success rate of two-stage revisions.<sup>12,13</sup> Although a complete one- or two-stage revision provides acceptable results regarding infection eradication, this comes at the cost of an extensive surgery with notable morbidity and bone loss for the patient. This is especially enhanced when one of the components is well-fixed to the bone. To cope with this predicament, some surgeons have proposed a partial revision, extracting only the loose component while preserving the well-fixed component. The first to propose this treatment method was Faroug et al<sup>14</sup> with a report on two patients undergoing successful selective revision, one of the acetabular shell and one of the femoral stem. The largest series on 31 patients was published by Ji et al,<sup>15</sup> in which an 87% success rate was reported.

The goals of our study were to review the published series and to establish the overall proportion of success after partial retention of a

well-fixed component in the management of chronic infected THA and to identify risk factors for failure of this treatment.

## Methods

### Search Strategy

We conducted a systematic review according to the methodology described in the Cochrane Handbook for Systematic Reviews of Interventions and reported according to the Preferred Reporting Items for Systematic Reviews and Meta-Analyses (PRISMA) statement.<sup>16</sup>

We searched the US National Library of Medicine (PubMed/MEDLINE), the Web of Science, and the Cochrane Database of Systematic Reviews in May 2018 for all studies published to that date. We used combinations of words pertaining to hip arthroplasty and PJIs, including the key words “Arthroplasty, Replacement, Hip”[Mesh] AND “Infection”[Mesh]. Only articles published in the English language were included. The search strings are available in Supplemental Appendix, Supplemental Digital Content 1, <http://links.lww.com/JAAOS/A418>. The PRISMA diagram describing the selection process is presented in Figure 1.

Dr. Domb or an immediate family member reports grants and other from American Orthopedic Foundation, during the conduct of the study; personal fees from Adventist Hinsdale Hospital; personal fees and nonfinancial support from Amplitude; grants, personal fees, and nonfinancial support from Arthrex, personal fees and nonfinancial support from DJO Global; grants from Kaufman Foundation, grants, personal fees, and nonfinancial support from Medacta; grants, personal fees, nonfinancial support, and other from Pacira Pharmaceuticals; grants, personal fees, nonfinancial support, and other from Stryker; grants from Breg, personal fees from Orthomerica; grants, personal fees, nonfinancial support, and other from Mako Surgical Corp; grants and nonfinancial support from Midwest Associates; grants from ATI Physical Therapy; grants, personal fees, and nonfinancial support from St. Alexius Medical Center; grants from Ossur, outside the submitted work; has a patent 8920497—method and instrumentation for acetabular labrum reconstruction with royalties paid to Arthrex, a patent 8708941—adjustable multicomponent hip orthosis with royalties paid to Orthomerica and DJO Global, and a patent 9737292—knottless suture anchors and methods of tissue repair with royalties paid to Arthrex; is the Medical Director of Hip Preservation at St. Alexius Medical Center; serves as a board member, owner, officer, or committee member of the American Hip Institute Research Foundation, AANA Learning Center Committee, the Journal of Hip Preservation Surgery, the Journal of Arthroscopy; and has had ownership interests in the American Hip Institute, Hinsdale Orthopedic Associates, Hinsdale Orthopedic Imaging, SCD#3, North Shore Surgical Suites, and Munster Specialty Surgery Center. None of the following authors or any immediate family member has received anything of value from or has stock or stock options held in a commercial company or institution related directly or indirectly to the subject of this article: Dr. Rosinsky, Dr. Greenberg, Dr. Amster-Kahn, Dr. Campenfeldt, and Dr. Kosashvili.

## Inclusion and Exclusion Criteria

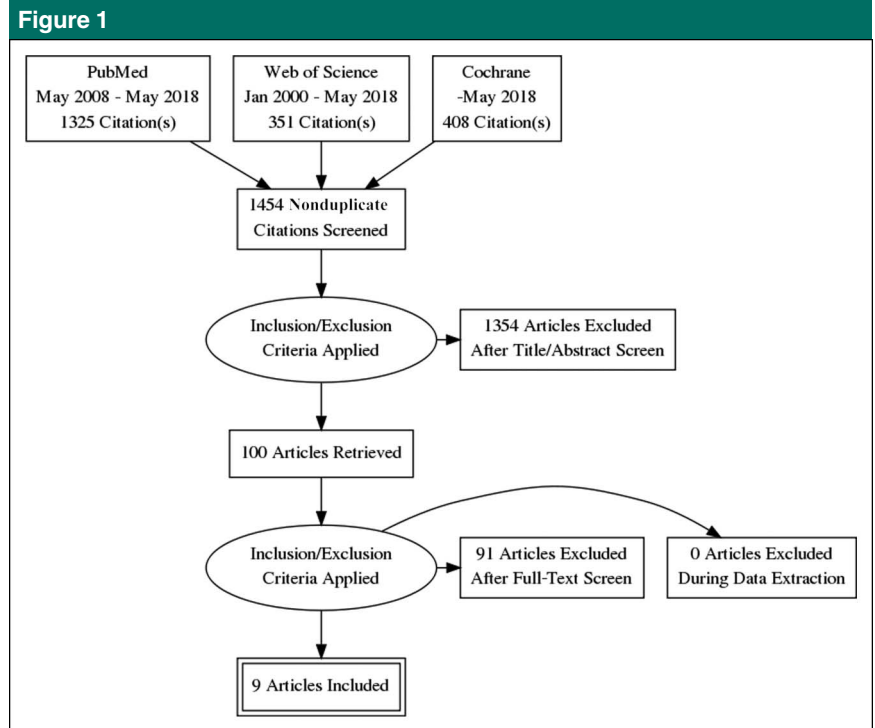
Studies were included if they reported on patients with a chronic infection of a hip implant undergoing selective component-retaining revision THA. The definition of a selective component-retaining revision was one in which either the acetabular or the femoral implant was retained, but not both. Studies were excluded if they were registry studies which did not enable specific data extraction, case reports with less than five patients, studies which involved joints other than hip joint, studies that did not report on survivorship of the implants, or studies reported in non-English publications.

## Study Selection

The results on PubMed, Cochrane, and Web of Science were screened for relevance by two independent observers. The observers began screening the article titles identified in the literature search and determined whether the article should be considered for inclusion. Since the screening process needed to distinguish between total and partial retention, any title that mentioned infection/septic, hip implant/arthroplasty, and revision was selected for additional review. The titles identified as potentially eligible were then screened at the abstract level, and finally, full-text reviews were done according to inclusion and exclusion criteria. A manual search of references and cited articles was done to identify any additional relevant studies for inclusion. Any disagreements were resolved by consensus with the two authors and a third independent reviewer.

## Methodological Quality Assessment

Two reviewers (PJR and AG) independently performed a methodolog-



Flow diagram of literature search conducted in May 2018 according to the Preferred Reporting Items for Systematic Review and Meta-analyses guidelines.

ical quality assessment based on the Methodological Index for Non-Randomized Studies (MINORS) (Supplemental Table 1, Supplemental Digital Content 2, <http://links.lww.com/JAAOS/A419>). MINORS has been shown to be a valid tool for assessment of methodological quality in nonrandomized surgical studies. Each of the items in the MINORS criteria is given a score of 0, 1, or 2, giving an ideal score of 16 for noncomparative studies and 24 for comparative studies.<sup>17</sup>

## Data Abstraction

Three reviewers (HAK, AG, and PC) independently extracted data from the relevant studies and recorded the data in *Microsoft Excel* (Microsoft Office 2011; Microsoft). Data on study design, sample size, component revised, indications for partial component-retaining revision, number of stages, surgical method, in-

fecting organism, complications, outcome scores, and survivorship were extracted from each study and used to assess study quality.

## Results

### Study Selection

The search resulted in 1,454 studies that were screened to determine outcomes of partial retention in chronic infection of a THA. Of these, 1,354 studies were excluded based on their title or abstract for clearly not meeting inclusion criteria. After full-text review, 91 studies were further excluded. Of these, one study was excluded for being a registry-based study with no particular data on the partial revisions and no data on exact chronicity of cases.<sup>18</sup> One study was excluded for being a case report with less than five patients.<sup>14</sup> After applying the screening process, a

total of nine studies, reporting on the outcome of 134 patients, were suitable for inclusion. The PRISMA flowchart describing this process is presented in Figure 1.

The studies included in this systematic review, along with demographics and MINORS score evaluation, are presented in Supplemental Table 2, Supplemental Digital Content 3, <http://links.lww.com/JAAOS/A420>. One study, by Lombardi et al,<sup>19</sup> included patients who were previously reported on by Ekpo et al.<sup>20</sup>

### Study Quality Assessment and Risk of Bias

All nine studies were retrospective, noncomparative, case series in design, and were assigned a level of evidence of IV based on the guidelines set out by Wright et al.<sup>21</sup> The average MINORS score of both reviewers and the summation is presented in Supplemental Table 3, Supplemental Digital Content 4, <http://links.lww.com/JAAOS/A421>. On average, the studies yielded a score of 8.77 of 16 (range, 5 to 12).

### General Description of Studies

Two studies were done in China<sup>15,22</sup>; two studies were done in the United States<sup>19,20</sup>; and one study was done in Canada,<sup>23</sup> Germany,<sup>24</sup> Japan,<sup>25</sup> South Korea,<sup>26</sup> and the United Kingdom.<sup>27</sup>

Of 134 patients, 61 were men and 73 were women with average age of 60.82 years (range 19 to 86 years). The average follow-up period was 60.56 months (range 4 to 217). Six studies used a two-stage revision surgery for surgical modality while three studies used a single-stage revision. A total of 64 (47.7%) patients underwent single-stage revision while 70 (52.3%) patients underwent two-stage surgery.

The indications and contraindications for surgery were not

uniform among the studies (Supplemental Table 4, Supplemental Digital Content 5, <http://links.lww.com/JAAOS/A422>). Some studies did not clearly state a general guideline for choosing this procedure.<sup>20,24</sup> Six studies clearly stated the need for proof of fixation on either plain radiography or advanced imaging,<sup>15,22,23,25–27</sup> and four stressed the need to assure fixation during the surgical procedure.<sup>15,22,23,26</sup> Two studies advocated using the procedure when no major comorbidities pre-existed,<sup>23,27</sup> while one study proposed the opposite, using this procedure in the presence of comorbidities and frailty, to minimize trauma to the patient.<sup>19</sup>

### Success Rates

The definition of success/failure was not uniform among the studies. Three of the studies simply stated “recurrence of infection” without detailing the diagnostic criteria<sup>19,25,26</sup>; Anagnostakos et al<sup>24</sup> added the specification of the “same bacterium”; two studies mentioned the need for “long-term” suppressive antibiotics<sup>20,23</sup>; Ji et al<sup>15</sup> added an evaluation of “clinical symptoms and signs”; and two studies described a reliance on inflammatory markers and radiographic findings.<sup>22,27</sup> The overall proportion of success after partial retention of well-fixed components in chronic infected hip arthroplasty was 89.41% (range 81.3% to 100%) (Supplemental Table 5, Supplemental Digital Content 6, <http://links.lww.com/JAAOS/A423>). The overall 1-year mortality rate was 0.7% (one patient). The weighted-average success rate of two-stage revision surgery was higher at 89.9% while the weighted-average success rate of one-stage revision surgery was 87.49%.

Retention of the femoral head and revision of the acetabular shell was done in 118 patients (88% of patients) while revision of the femoral

stem was done in 16 patients (12% of patients). In one study by El-Husseiny and Haddad,<sup>27</sup> the authors noted the subgroup of which component was revised, however, in report of outcomes combined both groups. These patients were excluded from the component analysis. The success rate in acetabular shell revision was higher than in femoral stem revision (90.43% versus 80%); however, the small number of femoral stem revisions precludes definitive conclusions (Supplemental Table 5, Supplemental Digital Content 6, <http://links.lww.com/JAAOS/A423>; Figures 2 and 3).

### Infectious Organisms

All nine studies reported on infectious organisms cultured; however, El-Husseiny and Haddad<sup>27</sup> and Lombardi et al<sup>19</sup> did not identify the organism in the failure cases and therefore could not be included in calculation of success rate by infectious organism (Table 1). In all nine studies, the single most common infectious agent was coagulase-negative *Staphylococcus aureus* in 31 of 114 (27.19%) culture-positive cases. Successful eradication rate in these patients was 92.3%. Methicillin-sensitive *Staphylococcus aureus* was positive in 25 patients, with eradication success rate of 88.88%. Methicillin-resistant *Staphylococcus aureus* was isolated in eight patients, and in these, eradication was successful in only 40%. Seven patients were infected with multiple bacteria, in which eradication rate was 100%. Forty-three patients were positive for other types of bacteria including *Pseudomonas*, *Enterobacter*, *Streptococcus*, and others. These patients were treated with antibiotics according to the specific sensitivity of each agent with a success rate of 94.2% in infection eradication. In 20 patients, there were no positive cultures, and

the infecting agent was not identified. These cases had an 88.8% success rate.

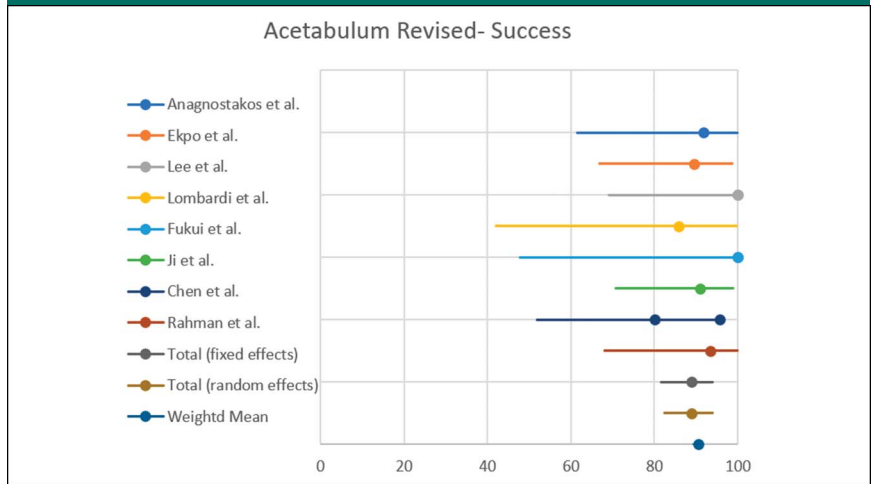
Postoperative intravenous antibiotics were continued for 6 weeks in three studies.<sup>19,20,23</sup> One study continued intravenous antibiotics for 4 weeks<sup>24</sup> and in two studies only for 5 and 14 days.<sup>15,27</sup> The remaining three studies did not report on their postoperative treatment of antibiotics.<sup>22,25,26</sup> Four studies reported on continuing oral antibiotics for 6.5 weeks on average.<sup>15,23,24,27</sup> The remaining studies did not report on postoperative oral antibiotic treatment.

## Discussion

We found an overall success rate approaching 90% in the treatment of chronically infected THA with selective component-retaining revision arthroplasty. This eradication rate is comparable with previous studies on one- or two-stage revision arthroplasty. A systematic review by Kuntz et al<sup>28</sup> compared results of 1- and 2-stage revisions and found success rates of 91.8% and 92.4%, respectively. A different systematic review found comparable results regarding infection eradication with slightly better functional outcomes in one-stage revisions.<sup>13</sup> The results of our systematic review are comparable with these studies and suggest that partial retention of well-fixed components is a feasible measure in the treatment of chronically infected THA.

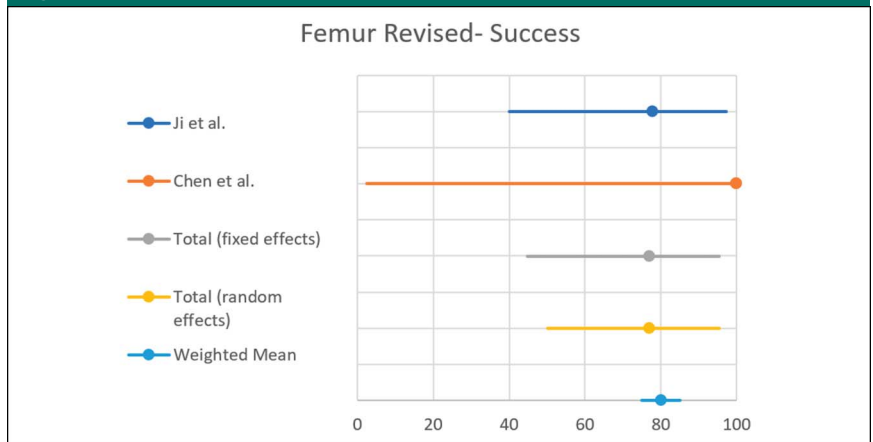
The possibility of retaining a well-fixed component in the face of a concurrent infection has in the past seemed implausible because of the concerns of bacterial adherence and subsequent biofilm formation. A proposed hypothesis for the success of this treatment may be that successful osteointegration precedes the invasion of bacteria to the bone-

**Figure 2**



Success rates in revision of acetabular shell of individual studies and weighted success rate.

**Figure 3**



Success rates in revision of femoral stem of individual studies and weighted success rate.

prosthesis interface. It would follow that the bone-prosthesis interface is not part of the effective joint space in these cases and renders the interface inaccessible to bacteria.<sup>23,26</sup> Morley et al<sup>29</sup> suggested this rationale also in the case of a well-fixed cement mantle in cases of PJI. Pellegrini et al<sup>30</sup> suggested using single photon emission CT to localize PJI and, in cases where the bone-prosthesis interface is not involved, suggested the possibility of DAIR alone. The

consensus of the Biofilm Workgroup during the second International Consensus Meeting on Musculoskeletal Infection determined that mapping of biofilm location, either with single photon emission CT or other advanced imaging modalities, is presently not applicable to the clinical setting.<sup>31</sup>

An especially intriguing possibility, one which was used in three studies, was the use of a one-stage revision in combination with fixed-component

**Table 1**

Type of Organism Cultured on Primary Infection		
Infectious Organism	Cases	Success Rates % <sup>a</sup>
CONS	31	92.3
MRSA	8	40
MSSA	25	88.88
Multiple organisms	7	100
Others	43	94.2
Culture negative	20	88.88

CONS = coagulase-negative *Staphylococcus*, MRSA = methicillin-resistant *Staphylococcus aureus*, MSSA = methicillin-sensitive *Staphylococcus aureus*  
<sup>a</sup> El-Husseiny and Haddad<sup>27</sup> and Lombardi et al<sup>19</sup> did not identify which infectious organism was cultured in the failure cases precluding calculation of success rates including these studies. Success rates are therefore based on the remaining seven studies.  
 Others—*Pseudomonas*, *Enterobacter*, *Streptococcus*, and other species.

retaining. These studies showed comparable results to the two-stage revisions, suggesting this may be a successful treatment as well.<sup>15,23,27</sup>

The studies included in this review are variable in design and methodology. All studies are noncomparative, and some include patient cohorts which were removed from this review either due to being acute infections,<sup>26</sup> including duplicates of patients,<sup>19</sup> and one due to incomplete data.<sup>27</sup>

To the best of our knowledge, one registry study reported on the success rate of partial retention revision in the treatment of infected THAs.<sup>18</sup> This study includes a substantial number of patients who might have met the criteria for inclusion in this present review and may have influenced our results. However, the registry study does not include crucial data for reaching conclusions regarding this treatment. First and foremost, the study does not report on the chronicity of the patients treated by partial retention. Second, no details on the method of treatment are reported. Finally, in treatment of these patients, it was not specified whether the acetabular or femoral implant was revised.

The relatively high success rates reported in this systematic review, in retention of a fixed single component,

may raise a discussion regarding the use of DAIR in chronic cases in which both components are fixed. This concept has previously been examined in a systematic review by Maillet et al,<sup>32</sup> which included six studies with a total of 29 patients. The studies included were very heterogeneous, consisting of case reports, with inconsistency regarding report on implant stability and varying follow-up periods. The pooled failure rate was 48%, and of patients completing at least 2 years of follow-up, failure occurred in 70%. These inferior results may reflect the fact that this group included a notable portion of patients in which a loose implant was retained, and DAIR was done because of patient frailty or low compliance.

Liebs,<sup>33</sup> in a commentary on El-Husseiny and Haddad,<sup>27</sup> stated the problems encountered when trying to design high-quality studies on this matter, stressing the difficulty in amassing a sufficient number of patients. Second, because of the novelty of this procedure, an effect size is still problematic to define, limiting the ability to do a power analysis. Third, the ability to decide on which patient a selective component-retaining procedure may be done is often an intro-operative decision,

thereby limiting the ability to perform prospective studies and reducing the homogeneity of studies. In addition, the unique characteristics of patients with PJI, including varying baseline medical condition, different infectious agents, and variability in surgical procedures, all limit ability to undertake large-scale studies, generalizable to other patients with PJI.

Despite these obstacles, retrospective matched studies, with longer follow-up, are possible and should be undertaken. Future studies should clearly state and abide to pre-determined surgical indications, as well as evaluate outcomes based on explicit definitions of success. Furthermore, registry studies may provide valuable information in cases where they contain specific and detailed relevant data. Animal studies, as well as other preclinical research, may develop methods to accurately assess the bone-prosthesis interface, thereby enabling better understanding of the extent of bio-film formation. Our hope is that this systematic review will contribute to the body of knowledge and enable future studies to be done at a higher methodological level.

In the Proceedings of International Consensus on Orthopedic Infections of 2018, 75% of experts in the field of joint reconstruction agreed that there may be circumstances when an implant is well-fixed, either by cement or through osseointegration, and the infective organisms are not able to access the prosthesis-bone interface. The conclusion was that in these cases, partial retention of well-fixed implants in certain patients, especially those with challenging conditions, may be a viable option. The need to do aggressive soft-tissue débridement and complete removal of infected implants was stressed.<sup>34</sup>

The limitations of this study are first and foremost the quality of studies included in the review. The

included studies lacked sufficient internal validity, sample size, methodological consistency, and standardization of protocols and outcomes. The studies are retrospective case series, with no prospective or matched studies included. Moreover, the patients in these studies were treated with varying surgical methods, including both one- and two-stage procedures, as well as by various centers, further contributing to the inherent bias. In addition, the total number of patients is relatively small. Finally, the follow-up in these studies was inconsistent, the definition of “success” was not uniform, and a clear description of the diagnostic criteria for infection recurrence was lacking. Although most included a follow-up period of at least 2 years, one study included patients with shorter follow-up times.<sup>19</sup>

In conclusion, a selective retainment of well-fixed components in the face of a chronically infected hip arthroplasty may be considered in certain situations. Although the reported success rate is high and is comparable with complete revision arthroplasty in cases of chronic infected THAs, the quality of the studies included is poor. There is a need for higher quality studies to definitively assess the safety and efficacy of selective component retainment in the treatment of chronic periprosthetic infection after THA.

## References

Levels of evidence are described in the table of contents. In this article, reference 5 is a level III study. References 6, 9-15, 19, 20, 22-29, and 32 are level IV studies.

References printed in **bold type** are those published within the past 5 years.

- Sloan M, Premkumar A, Sheth NP: Projected volume of primary total joint arthroplasty in the U.S., 2014 to 2030. *J Bone Joint Surg Am* 2018;100:1455-1460.
- Gwam CU, Mistry JB, Mohamed NS, et al: Current epidemiology of revision total hip arthroplasty in the United States: National inpatient sample 2009 to 2013. *J Arthroplasty* 2017;32:2088-2092.
- Leitner L, Türk S, Heindinger M, et al: Trends and economic impact of hip and knee arthroplasty in central Europe: Findings from the Austrian National Database. *Sci Rep* 2018;8:4707.
- Patel A, Pavlou G, Mújica-Mota RE, Toms AD: The epidemiology of revision total knee and hip arthroplasty in England and Wales: A comparative analysis with projections for the United States. A study using the National Joint Registry dataset. *Bone Joint J* 2015;97-B:1076-1081.
- Gundtoft PH, Pedersen AB, Varnum C, Overgaard S: Increased mortality after prosthetic joint infection in primary THA. *Clin Orthop Relat Res* 2017;475:2623-2631.
- Shahi A, Tan TL, Chen AF, Maltenfort MG, Parvizi J: In-hospital mortality in patients with periprosthetic joint infection. *J Arthroplasty* 2017;32:948-952.e1.
- Kurtz S, Ong K, Lau E, Mowat F, Halpern M: Projections of primary and revision hip and knee arthroplasty in the United States from 2005 to 2030. *J Bone Joint Surg Am* 2007;89:780-785.
- Kurtz SM, Lau E, Watson H, Schmier JK, Parvizi J: Economic burden of periprosthetic joint infection in the United States. *J Arthroplasty* 2012;27:61-65.e1.
- Tsakayama DT, Estrada R, Gustilo RB: Infection after total hip arthroplasty. A study of the treatment of one hundred and six infections. *J Bone Joint Surg Am* 1996;78:512-523.
- Kunutsor SK, Beswick AD, Whitehouse MR, Wyld V, Blom AW: Debridement, antibiotics and implant retention for periprosthetic joint infections: A systematic review and meta-analysis of treatment outcomes. *J Infect* 2018;77:479-488.
- Berend KR, Lombardi AV, Morris MJ, Bergeson AG, Adams JB, Sneller MA: Two-stage treatment of hip periprosthetic joint infection is associated with a high rate of infection control but high mortality. *Clin Orthop Relat Res* 2013;471:510-518.
- Lange J, Troelsen A, Thomsen RW, Søballe K: Chronic infections in hip arthroplasties: Comparing risk of reinfection following one-stage and two-stage revision: A systematic review and meta-analysis. *Clin Epidemiol* 2012;4:57-73.
- Leonard HAC, Liddle AD, Burke O, Murray DW, Pandit H: Single- or two-stage revision for infected total hip arthroplasty? A systematic review of the literature. *Clin Orthop* 2014;472:1036-1042.
- Faroug R, Shah Y, McCarthy MJH, Halawa M: Two stage one component revision in infected total hip replacements—Two case reports and literature review. *Hip Int* 2009;19:292-298.
- Ji B, Xu B, Guo W, et al: Retention of the well-fixed implant in the single-stage exchange for chronic infected total hip arthroplasty: An average of five years of follow-up. *Int Orthop* 2017;41:901-909.
- Liberati A, Altman DG, Tetzlaff J, et al: The PRISMA statement for reporting systematic reviews and meta-analyses of studies that evaluate health care interventions: Explanation and elaboration. *J Clin Epidemiol* 2009;62:e1-e34.
- Slim K, Nini E, Forestier D, Kwiatkowski F, Panis Y, Chipponi J: Methodological index for non-randomized studies (minors): Development and validation of a new instrument. *ANZ J Surg* 2003;73:712-716.
- Engesaeter LB, Dale H, Schrama JC, Hallan G, Lie SA: Surgical procedures in the treatment of 784 infected THAs reported to the Norwegian Arthroplasty Register. *Acta Orthop* 2011;82:530-537.
- Lombardi AV, Berend KR, Adams JB: Partial two-stage exchange of the infected total hip replacement using disposable spacer moulds. *Bone Joint J* 2014;96-B:66-69.
- Ekpo TE, Berend KR, Morris MJ, Adams JB, Lombardi AV: Partial two-stage exchange for infected total hip arthroplasty: A preliminary report. *Clin Orthop Relat Res* 2014;472:437-448.
- Wright JG, Swiontkowski MF, Heckman JD: Introducing levels of evidence to the journal. *J Bone Joint Surg Am* 2003;85:1-3.
- Chen KH, Tsai SW, Wu PK, Chen CF, Wang HY, Chen WM: Partial component-retained two-stage reconstruction for chronic infection after uncemented total hip arthroplasty: Results of sixteen cases after five years of follow-up. *Int Orthop* 2017;41:2479-2486.
- Rahman WA, Kazi HA, Gollish JD: Results of single stage exchange arthroplasty with retention of well fixed cement-less femoral component in management of infected total hip arthroplasty. *World J Orthop* 2017;8:264-270.
- Anagnostakos K, Jung J, Kelm J, Schmitt E: Two-stage treatment protocol for isolated septic acetabular cup loosening. *Hip Int* 2010;20:320-326.
- Fukui K, Kaneuji A, Ueda S, Matsumoto T: Should well-fixed uncemented femoral components be revised in infected hip arthroplasty? Report of five trial cases. *J Orthop* 2016;13:437-442.
- Lee YK, Lee KH, Nho JH, Ha YC, Koo KH: Retaining well-fixed cementless stem in the treatment of infected hip arthroplasty. *Acta Orthop* 2013;84:260-264.

27. El-Husseiny M, Haddad FS: The role of highly selective implant retention in the infected hip arthroplasty. *Clin Orthop* 2016;474:2157-2163.
28. Kunutsor SK, Whitehouse MR, Blom AW, Beswick AD; INFORM Team: Re-infection outcomes following one- and two-stage surgical revision of infected hip prosthesis: A systematic review and meta-analysis. *PLoS One* 2015;10:e0139166.
29. Morley JR, Blake SM, Hubble MJW, Timperley AJ, Gie GA, Howell JR: Preservation of the original femoral cement mantle during the management of infected cemented total hip replacement by two-stage revision. *J Bone Joint Surg Br* 2012; 94:322-327.
30. Pellegrini A, Legnani C, Meani E: A new perspective on current prosthetic joint infection classifications: Introducing topography as a key factor affecting treatment strategy. *Arch Orthop Trauma Surg* 2019;139:317-322.
31. Saeed K, McLaren AC, Schwarz EM, et al: 2018 international consensus meeting on musculoskeletal infection: Summary from the biofilm workgroup and consensus on biofilm related musculoskeletal infections. *J Orthop Res* 2019;37: 1007-1017.
32. Maillet M, Pavese P, Bruley D, Seigneurin A, François P: Is prosthesis retention effective for chronic infections in hip arthroplasties? A systematic literature review. *Eur J Clin Microbiol Infect Dis* 2015;34:1495-1502.
33. Liebs TR: CORR Insights(®): The role of highly selective implant retention in the infected hip arthroplasty. *Clin Orthop* 2016;474:2164-2167.
34. Abouljoud MM, Backstein D, Battenberg A, et al: Hip and knee section, treatment, surgical technique: Proceedings of international consensus on orthopedic infections. *J Arthroplasty* 2019;34:S445-S451.