

## Arthroscopic ligamentum teres reconstruction of the hip in Ehlers-Danlos syndrome: a case study

Jon E. Hammarstedt<sup>1</sup>, John M. Redmond<sup>2</sup>, Asheesh Gupta<sup>3</sup>, Benjamin G. Domb<sup>4</sup>

<sup>1</sup> University of Illinois at Chicago, Chicago, Illinois - USA

<sup>2</sup> Mayo Clinic, Jacksonville, Florida - USA

<sup>3</sup> NoVa Orthopedic & Spine Care, Woodbridge, Virginia - USA

<sup>4</sup> Hinsdale Orthopaedics, American Hip Institute, Westmont, Illinois - USA

### ABSTRACT

**Background:** Ehlers-Danlos syndrome (EDS) is a genetic disorder that affects the structural integrity of collagen within the body. This presents clinically as a connective tissue disorder with increased elasticity of joints, muscles, and ligaments. Multiple joints are affected by hypermobility and joint injury is common in these patients. It is estimated that EDS occurs once in every 5,000 births worldwide.

**Case review:** This article focuses on reconstruction of the ligamentum teres (LT) of the hip using a tibialis anterior allograft to treat severe instability and pain in a 43 year-old female with EDS. The LT reconstruction was accompanied by labral repair and capsular plication. The patient was assessed pre- and postoperatively using modified Harris Hip Score (mHHS), Hip Outcome Score Activities of Daily Living (HOS-ADLS), Hip Outcome Score Sports Specific Subscale (HOS-SSS), Non Arthritic Hip Score (NAHS), Visual Analog Scale (VAS), and satisfaction. One year following surgery the patient has reported positive outcomes in terms of pain and instability.

**Literature review:** Ligament reconstruction has been reported in patients with Ehlers-Danlos syndrome for shoulders and knees with positive results and restoration of stability. Currently there is a paucity of literature regarding patients with EDS undergoing hip procedures. In addition, reconstruction of the ligamentum teres for hip instability and pain has rarely been reported in a normal patient cohort.

**Clinical relevance:** This is the first study to report ligamentum teres reconstruction of the hip in a patient with Ehlers-Danlos syndrome and hip instability. The patient demonstrated satisfactory results 1 year from surgery.

**Keywords:** Ehler Danlos syndrome, Ligamentum teres reconstruction, Hip, Arthroscopy, Allograft, Outcomes

### Introduction

Ehlers-Danlos syndrome (EDS) is a genetic disorder which affects the structural integrity of collagen within the body (1). It is estimated that EDS occurs once in every 5,000 births worldwide (2). Genetic mutations alter the production, structure, and processing of collagen that may weaken connective tissue. Signs of this disease may be detected in the musculoskeletal, skin, and cardiovascular systems and range from flexible joints to fragile skin and heart disease. Currently, there are 6 classifications for EDS with diagnosis through genetic testing and clinical presentation (Tab. I). Rarely does a patient exclu-

sively exhibit the traits of 1 classification. Within the musculoskeletal system, the structural elasticity of joints, muscles, and ligaments are increased in patients with EDS, leading to an increased prevalence of orthopaedic injury (3, 4).

The increased elasticity of ligaments may cause laxity that leads to instability with subluxation or dislocation of the joint. Some studies have shown inferior outcomes in patients with ligamentous laxity undergoing anterior cruciate ligament reconstruction (5). However, case reports have demonstrated successful surgical intervention in patients with EDS (6-8). Ligament reconstruction has been reported in patients with EDS for shoulders and knees with positive results and restoration of stability. The positive results seen with some orthopaedic interventions to treat ligamentous laxity of patients with EDS suggest that similar results may be obtained in the hip.

Hip arthroscopy has been used to treat instability with ligamentum teres (LT) reconstruction and capsular plication in addition to femoroacetabular impingement with positive outcomes (9, 10). To date, reconstruction of the ligamentum teres for hip instability and pain has rarely been reported (11). This study reports the treatment of a patient with Ehlers-Danlos syndrome presenting for hip pain and instability with LT reconstruction using a tibialis anterior allograft.

Accepted: January 11, 2015

Published online: April 23, 2015

### Corresponding author:

Benjamin G. Domb  
Hinsdale Orthopaedics  
American Hip Institute  
1010 Executive Court  
Suite 250  
Westmont, IL 60559, USA  
DrDomb@americanhipinstitute.org

**TABLE I** - The 6 current classifications of Ehlers-Danlos syndrome

The current classifications of Ehlers-Danlos syndrome		
Common name	Type	Clinical presentation
Classical	I	- Skin laxity
	II	- Joint hypermobility
Hypermobility	III	- Skin laxity
		- Joint hypermobility
		- Joint dislocation
		- Joint pain
Vascular	IV	- Thin translucent skin
		- Acrogeria
		- Early onset of varicose veins
		- Hypermobility of small joints
		- Characteristic facial appearance
Kyphoscoliosis	VI	- General joint hypermobility
		- Muscle hypotonia
		- Scoliosis at birth
Arthrochalasia	VII A	- Severe general joint hypermobility
	VII B	- Recurrent dislocation
Dermatosparaxis	VII C	- Congenital bilateral hip dislocations
		- Skin fragility
		- Excessive bruising

### Case report

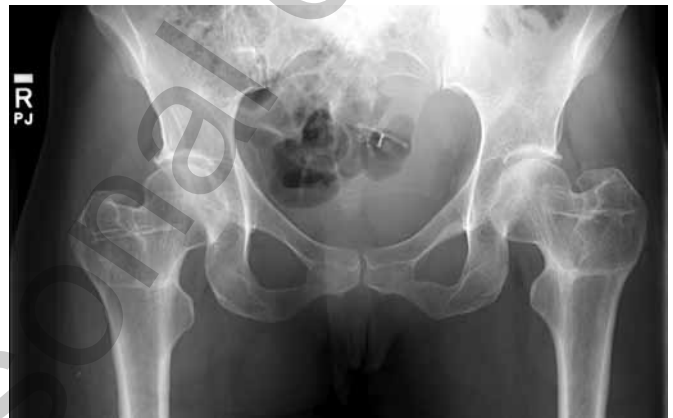A 43-year-old female with Ehlers-Danlos syndrome presented with bilateral hip pain for 3 months; the right hip was more bothersome than the left. At the age of 27, the patient was diagnosed with type 2 and type 3 EDS via collagen typing from a skin sample. She had known hypermobility throughout her life. At the time of presentation, the pain was localised to the posterolateral aspect of the hip and the groin. She described sensations of instability which caused her hip to give out posteriorly and anteriorly depending on positioning. However, the patient reported no history of frank dislocation. Her past orthopaedic history was notable for previous bilateral femoral rotational osteotomies over 15 years prior to our clinic presentation to reduce anterior instability caused by excessive femoral anteversion.

On clinical presentation, the patient underwent physical examination for provocative, tenderness, range of motion (Tab. II), and strength testing. She was noted to have positive anterior, lateral, and posterior impingement tests bilaterally. She described pain and instability with both anterior and posterior rotation-translation apprehension tests bilaterally (12). Her dial test was positive bilaterally. She was noted to have recurvatum of the elbows and knees, and general hypermobility of her joints. The patient was neurovascularly intact with no gross deformity of the hip girdle.

The patient underwent standard radiographic evaluation of her right hip with a standing and supine anteroposterior pelvis, 45 degree Dunn view, false profile view, and cross table lateral (Fig. 1). The anterior centre-edge angle (ACEA)

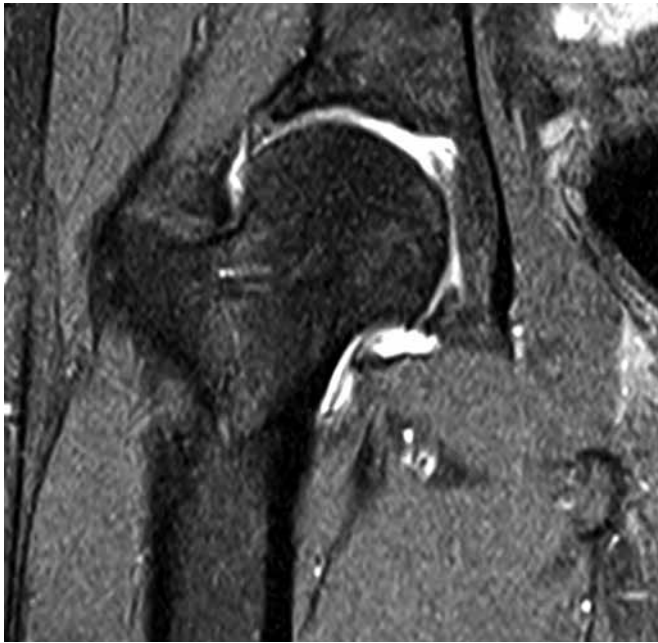**TABLE II** - Preoperative flexion, internal rotation, external rotation and abduction

	Left	Right
Range of Motion		
Flexion	110°	100°
Internal Rotation	10°	10°
External Rotation	45°	45°
Abduction	40°	30°

**Fig. 1** - Preoperative anteroposterior supine radiograph of 43 year-old female with Ehlers-Danlos syndrome.**TABLE III** - Preoperative radiographic measurements for anterior centre edge angle (ACEA), lateral centre edge angle (LCEA), acetabular inclination (AI), crossover and alpha angle

Radiographic Measurement	Pre-Operative
Anterior Centre-edge Angle (ACEA)	32°
Lateral Centre-edge Angle (LCEA)	28°
Acetabular Inclination (AI)	2°
Crossover	0°
Femoral Anteversion (MRA)	24°
Alpha Angle (X-Ray)	42°
Alpha Angle (MRA)	54°
Tonnis	1

was measured to be 32°, the lateral centre edge angle (LCEA) measured 28°, acetabular inclination (AI) measured 2°, and crossover sign measured 0° (Tab. III). Magnetic resonance arthrography revealed an anterior superior acetabular labral tear with mild to moderate chondral thinning superiorly and superior laterally in the hip joint. A type I tear (13) (complete tear) of the ligamentum teres was visualised (Fig. 2). Femoral anteversion was measured to be 24° on MRI by referencing



**Fig. 2** - Magnetic resonance arthrogram depicting ligamentum teres tear and torn labrum of the right hip.

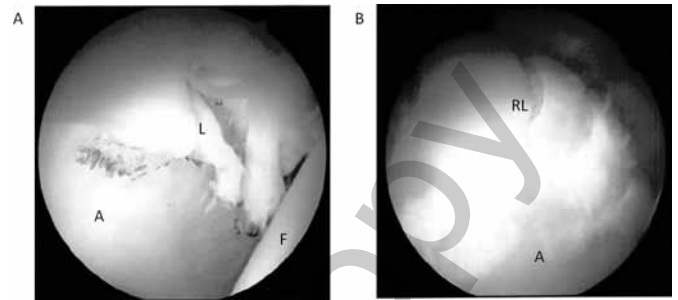
from the posterior femoral condyles and a line through the centre of the neck in the axial oblique plane. The patient was determined to be a candidate for arthroscopic LT reconstruction, capsular plication, and labral treatment.

The patient was assessed with surveys for modified Harris Hip Score (mHHS), Hip Outcome Score Activities of Daily Living (HOS-ADLS), Hip Outcome Score Sports Specific Subscale (HOS-SSS), Non Arthritic Hip Score (NAHS), Visual Analogue Scale (VAS), and satisfaction preoperatively, 3 months postoperatively, and 1 year postoperatively.

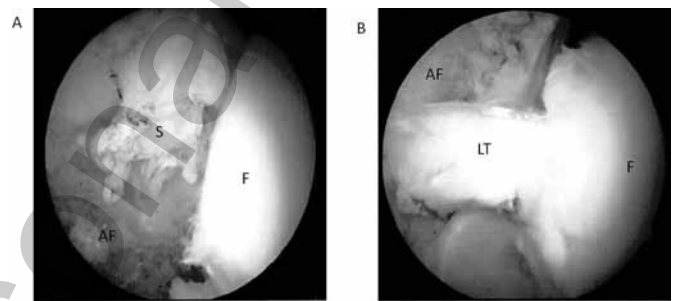
### Arthroscopic findings

The patient was placed in the supine position with a well-padded peroneal post and the feet well secured. Traction was applied under fluoroscopy and 3 portals were created: 1) anterolateral portal, 2) distal lateral portal, and 3) mid-anterior portal. A Beaver blade was used to perform the capsulotomy and a diagnostic arthroscopy was performed. The arthroscopic findings revealed a Seldes (14) type I and II tear of the labrum which extended from 12 o'clock to 3 o'clock and a grade 3 acetabular labrum articular disruption (ALAD) lesion comprising 1.5 square cm of cartilage on the acetabulum in the transitional zone. The cartilage lesion was not full thickness and a microfracture procedure was not performed. The remainder of the cartilage in the weight-bearing areas of the femur and acetabulum were intact. There was a full thickness tear of the ligamentum teres and upon pressure from a probe; the capsule had greater laxity than normal, consistent with instability.

Upon inspection, the labrum appeared amenable to repair and a labral repair was undertaken using a looped stitch technique (Fig. 3). A total of 4 fiberwire stitches (Arthrex, Naples, FL) and PushLock anchors (Arthrex, Naples, FL) were



**Fig. 3** - Acetabular labrum: **A)** before; and **B)** after labral repair using looped stitch technique with 4 stitches and anchors in a 43-year-old patient with Ehlers-Danlos syndrome. A = acetabulum; L = labrum; F = femoral head; RL = repaired labrum.

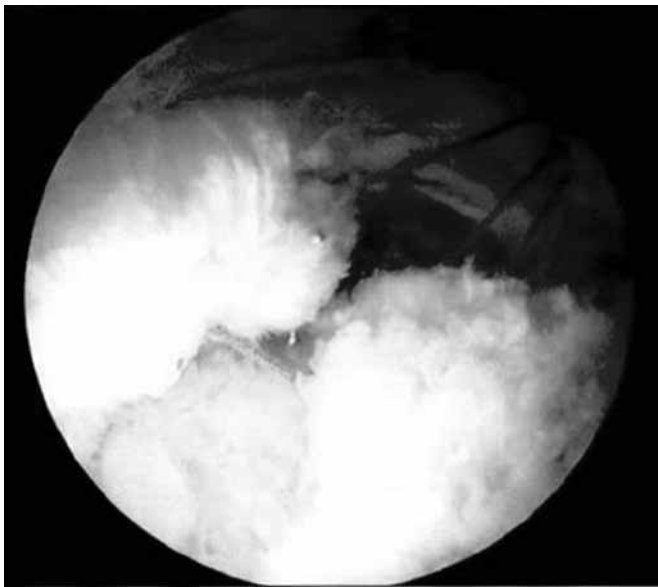


**Fig. 4** - Ligamentum teres: **A)** absent; and **B)** reconstructed using transtrochanteric tunnel and tibialis anterior allograft technique in a 43 year-old patient with Ehlers-Danlos syndrome. S = synovium; AF = acetabular fossa; LT = ligamentum teres; F = femoral head.

used to secure the labrum to the acetabular rim. Following labral repair we elected to proceed with LT reconstruction using a previously described technique (15). A 3.2 mm transtrochanteric guide pin was drilled under fluoroscopic guidance to exit the femoral fovea. An 8 mm cannulated reamer was then used over the guide pin to create a femoral tunnel and the acetabular tunnel. Care was taken to place the tunnel on the footprint of the ligamentum insertion, posterior to the obturator vessel (Fig. 4). An 8 mm tibialis anterior allograft to approximate the size and thickness of the LT was inserted through the femoral and acetabular tunnel with a cortical button used to secure the allograft to the quadrilateral plate of the pelvis. The graft was appropriately tensioned and fixated in the femoral tunnel using a PEEK interference screw (Arthrex, Naples, FL). Capsular plication was then completed using four Vicryl stitches (Ethicon, Somerville, NJ) (Fig. 5) (16, 17).

Postoperatively, rehabilitation instructions included 8 weeks of crutches with 20 pounds of flatfoot weight-bearing. A hip brace was to be worn for 8 weeks with motion limitations including flexion (0° to 90°), no abduction, and no external rotation.

One year postoperatively, the patient has reported sustained resolution of her feelings of instability. The patient reported gains in mHHS, HOS-ADLS, HOS-SSS and NAHS from preoperative baseline. The results are displayed in Table IV and Figure 6. The patient reported an increase in mHHS from



**Fig. 5** - Capsular plication in a 43-year-old patient with Ehlers-Danlos syndrome.

**TABLE IV** - Preoperative and postoperative patient-reported outcomes for modified Harris Hip Score (mHHS), Hip Outcome Score Activities of Daily Living (HOS-ADLS), Hip Outcome Score Sports Specific Subscale (HOS-SSS), Non Arthritic Hip Score (NAHS), Visual Analogue Scale (VAS), and satisfaction

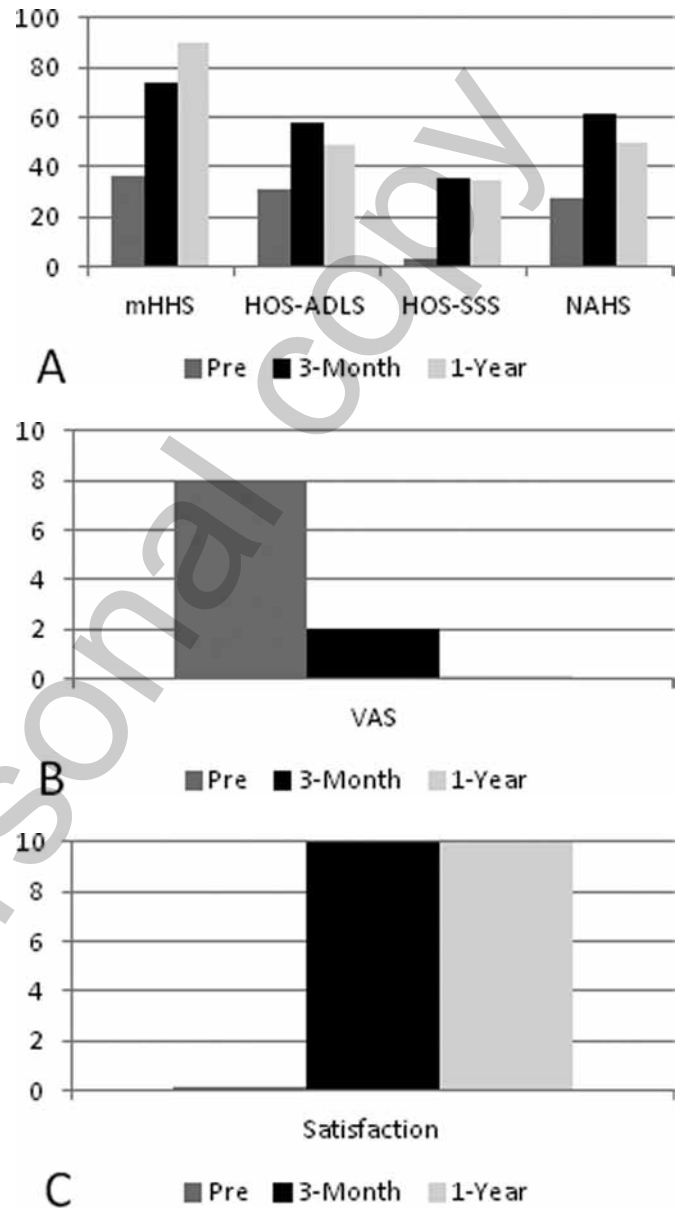
	mHHS	HOS-ADLS	HOS-SSS	NAHS	VAS	Satisfaction
Pre	36.3	30.9	3.1	27.5	8	0
3-Month	73.6	57.8	35.0	61.3	2	10
1-Year	90.1	48.5	34.4	50.0	0	10

36.3 in her preoperative score to 90.1 at the 1-year survey. Score increases of 30.9 to 48.5 for HOS-ADLS, 3.1 to 34.4 for HOS-SSS and 27.5 to 50.0 for NAHS were recorded. VAS, measuring pain, was scored an 8 before surgery indicating a significant level of pain and discomfort. At 3 months and 1 year postoperatively, those scores were 2 and 0 respectively. Satisfaction from the procedure was reported at 10 for those same postoperative time points. The patient reported no complications.

**Discussion**

Ehlers-Danlos syndrome affects the structure and production of collagen, presenting clinically as ligamentous laxity. The ligamentum teres is currently under investigation for its potential role in hip stability and pain. In this patient with Ehlers-Danlos syndrome and hip instability, ligamentum teres reconstruction with tibialis allograft demonstrated satisfactory results 1 year from surgery.

Hip instability remains difficult and controversial to define. In addition to physical exam findings, radiographic measure-



**Fig. 6** - Preoperative and postoperative patient-reported outcomes for: **A)** modified Harris Hip Score (mHHS), Hip Outcome Score Activities of Daily Living (HOS-ADLS), Hip Outcome Score Sports Specific Subscale (HOS-SSS), Non Arthritic Hip Score (NAHS); **B)** Visual Analogue Scale (VAS), and **C)** satisfaction.

ments consistent with dysplasia may indicate hip instability. Larson et al described the importance of acetabular and femoral version in hip stability (18). They conclude that excessive anteversion or retroversion by either the acetabulum or femur can lead to instability and impingement. As measured with radiographs, this patient displayed normal acetabular version with a crossover sign of 0 degrees. Femoral anteversion was measured to be 24° on MRI, which is slightly anteverted (19, 20). However, Jackson et al studied the role of femoral version on clinical outcomes after hip arthroscopy and found no difference between the retroverted, normal and anteverted groups (21).





Acetabular coverage has also been proposed as an indicator of hip instability. In a study by Clohisy et al (22), several measurements are described that depict acetabular coverage and are used to determine dysplasia. The anteroposterior pelvis radiograph can be used to measure the lateral centre edge angle and acetabular inclination, while the false-profile radiograph may be used to measure the anterior centre edge angle. Numerous studies have described acetabular undercoverage as a source of instability. Current literature describes an ACEA less than 20°, LCEA less than 25°, and AI greater than 10° as measures for acetabular undercoverage and indicative of instability. The patient in this study did not demonstrate any of the radiographic measures for instability with preoperative ACEA of 32°, LCEA of 27° and AI of 2°. Therefore, we concluded that the instability was from ligamentous laxity and not bony morphology.

The ligamentum teres is a pyramidal structure located in the hip joint emerging from the acetabular fossa, connecting to the femoral head (13, 23). The LT has been shown to have similar tensile strength to the anterior cruciate ligament and is thought to tighten with extension-internal rotation or flexion-external rotation (10, 24, 25). While the specific role and function of the ligament is currently unknown, studies have shown that the LT may serve a role in hip stability (23, 26-28).

Philippon et al assessed 4 patients experiencing instability that underwent ligamentum teres reconstruction (11). In total 3 patients experienced gains in the mHHS at 1 year postoperative, while 1 patient with advanced arthritis progressed to a hip replacement. The authors concluded that arthroscopic ligamentum teres reconstruction can successfully reduce symptoms of pain and instability in select patients. Byrd et al studied 23 patients experiencing persistent hip pain after a traumatic incident that cause a complete or partial tear of the LT (23). Upon assessing patient-reported outcomes, they concluded that arthroscopic intervention is an effective treatment for select patients. Our patient differs from normal patient populations due to the inherent instability and ligamentous laxity associated with her Ehlers-Danlos syndrome.

Hip arthroscopy is a common treatment for pain related to femoroacetabular impingement; and, in some cases, borderline dysplasia (29). Intraoperatively, a tear of the ligamentum teres may be seen, and is often treated with debridement. An effective debridement will be limited to the frayed fibres of the LT to avoid disruption of potential proprioception and nociception (23). While indications for LT reconstruction remain undefined, the treatment may be effective for continued pain and instability caused by a complete tear in the appropriate patient (11, 30).

## Disclosures

Financial support: None.

Conflict of interest: BGD has the following disclosures: American Hip Institute (AHI) Boardmember, AANA Learning Center Committee member.

AHI research support from: AHI; Arthrex, Inc.; Mako Surgical Corp.; Breg; ATI; Pacira.

Consulting: Arthrex, Inc.; Mako Surgical Corp.; Pacira.

Stock: Stryker.

Royalties: Orthomerica; DJO Global; Arthrex.

## References

1. Lawrence EJ. The clinical presentation of Ehlers-Danlos syndrome. *Adv Neonatal Care*. 2005;5(6):301-314.
2. Parapia LA, Jackson C. Ehlers-Danlos syndrome—a historical review. *Br J Haematol*. 2008;141(1):32-35.
3. Beighton P, Horan F. Orthopaedic aspects of the Ehlers-Danlos syndrome. *J Bone Joint Surg Br*. 1969;51(3):444-453.
4. Stanitski DF, Nadjarian R, Stanitski CL, Bawle E, Tsiopoulos P. Orthopaedic manifestations of Ehlers-Danlos syndrome. *Clin Orthop Relat Res*. 2000;376:213-221.
5. Kim SJ, Kumar P, Kim SH. Anterior cruciate ligament reconstruction in patients with generalized joint laxity. *Clin Orthop Surg*. 2010;2(3):130-139.
6. Badia A, Riano F, Young LC. Bilateral arthroscopic tendon interposition arthroplasty of the thumb carpometacarpal joint in a patient with Ehlers-Danlos syndrome: a case report. *J Hand Surg Am*. 2005;30(4):673-676.
7. Simonian PT, Luck JV Jr. Synthetic posterior cruciate ligament reconstruction and below-knee prosthesis use in Ehlers-Danlos syndrome. *Clin Orthop Relat Res*. 1993;(294):314-317.
8. Aldridge JM III, Perry JJ, Osbahr DC, Speer KP. Thermal capsulorrhaphy of bilateral glenohumeral joints in a pediatric patient with Ehlers-Danlos syndrome. *Arthroscopy*. 2003;19(5):E41.
9. Larson CM, Giveans MR. Arthroscopic management of femoroacetabular impingement: early outcomes measures. *Arthroscopy*. 2008;24(5):540-546.
10. Kelly BT, Williams RJ III, Philippon MJ. Hip arthroscopy: current indications, treatment options, and management issues. *Am J Sports Med*. 2003;31(6):1020-1037.
11. Philippon MJ, Pennock A, Gaskill TR. Arthroscopic reconstruction of the ligamentum teres: technique and early outcomes. *J Bone Joint Surg Br*. 2012;94(11):1494-1498.
12. Shu B, Safran MR. Hip instability: anatomic and clinical considerations of traumatic and atraumatic instability. *Clin Sports Med*. 2011;30(2):349-367.
13. Gray AJ, Villar RN. The ligamentum teres of the hip: an arthroscopic classification of its pathology. *Arthroscopy*. 1997;13(5):575-578.
14. Seldes RM, Tan V, Hunt J, Katz M, Winiarsky R, Fitzgerald RH Jr. Anatomy, histologic features, and vascularity of the adult acetabular labrum. *Clin Orthop Relat Res*. 2001;382:232-240.
15. Lindner D, Sharp KG, Trenga AP, Stone J, Stake CE, Domb BG. Arthroscopic ligamentum teres reconstruction. *Arthrosc Tech*. 2013;2(1):e21-e25.
16. Domb BG, Stake CE, Lindner D, El-Bitar Y, Jackson TJ. Arthroscopic capsular plication and labral preservation in borderline hip dysplasia: two-year clinical outcomes of a surgical approach to a challenging problem. *Am J Sports Med*. 2013;41(11):2591-2598.
17. Domb BG, Philippon MJ, Giordano BD. Arthroscopic capsulotomy, capsular repair, and capsular plication of the hip: relation to atraumatic instability. *Arthroscopy*. 2013;29(1):162-173.
18. Larson CM, Stone RM. Current concepts and trends for operative treatment of FAI: hip arthroscopy. *Curr Rev Musculoskelet Med*. 2013;6(3):242-249.
19. Tönnis D, Heinecke A. Acetabular and femoral anteversion: relationship with osteoarthritis of the hip. *J Bone Joint Surg Am*. 1999;81(12):1747-1770.
20. Fabry G, MacEwen GD, Shands AR Jr. Torsion of the femur. A follow-up study in normal and abnormal conditions. *J Bone Joint Surg Am*. 1973;55(8):1726-1738.
21. Jackson TJ, Lindner D, El-Bitar YF, Domb BG. Effect of Femoral Anteversion on Clinical Outcomes After Hip Arthroscopy. *Arthroscopy*. 2014.

22. Clohisy JC, Carlisle JC, Beaulé PE, et al. A systematic approach to the plain radiographic evaluation of the young adult hip. *J Bone Joint Surg Am.* 2008;90(Suppl 4):47-66.
23. Byrd JW, Jones KS. Traumatic rupture of the ligamentum teres as a source of hip pain. *Arthroscopy.* 2004;20(4):385-391.
24. Martin RL, Palmer I, Martin HD. Ligamentum teres: a functional description and potential clinical relevance. *Knee Surg Sports Traumatol Arthrosc.* 2012;20(6):1209-1214.
25. Wenger D, Miyanji F, Mahar A, Oka R. The mechanical properties of the ligamentum teres: a pilot study to assess its potential for improving stability in children's hip surgery. *J Pediatr Orthop.* 2007;27(4):408-410.
26. Amenabar T, O'Donnell J. Arthroscopic ligamentum teres reconstruction using semitendinosus tendon: surgical technique and an unusual outcome. *Arthrosc Tech.* 2012;1(2):e169-e174.
27. Kivlan BR, Richard Clemente F, Martin RL, Martin HD. Function of the ligamentum teres during multi-planar movement of the hip joint. *Knee Surg Sports Traumatol Arthrosc.* 2013;21(7):1664-1668.
28. Savory WS. The Use of the Ligamentum Teres of the Hip-joint. *J Anat Physiol.* 1874;8(Pt 2):291-296.
29. Shetty VD, Villar RN, Ilizaliturri VM. Hip arthroscopy: current concepts and review of literature. *Br J Sports Med.* 2007;41(2):64-68, discussion 68.
30. Simpson JM, Field RE, Villar RN. Arthroscopic reconstruction of the ligamentum teres. *Arthroscopy.* 2011;27(3):436-441.

Author personal copy