

Arthroscopic Labral Base Repair in the Hip: Clinical Results of a Described Technique

Timothy J. Jackson, M.D., Bryan Hanypsiak, M.D., Christine E. Stake, M.A., Dror Lindner, M.D., Youssef F. El Bitar, M.D., and Benjamin G. Domb, M.D.

Purpose: The purpose of this study was to evaluate the clinical outcomes of a cohort of patients who underwent labral repair by use of a previously published labral base repair suture technique for the treatment of acetabular labral tears and pincer-type femoroacetabular impingement (FAI). **Methods:** Patients who received hip arthroscopy for symptomatic intra-articular hip disorders and underwent the previously described labral base repair technique were included in the study group. Patients who had Tönnis arthritis grade 2 or greater, had Legg-Calves-Perthes disease, or underwent simple looped stitch repair were excluded. The patient-reported outcome scores included the modified Harris Hip Score, the Non-Arthritic Hip Score, the Hip Outcome Score—Activities of Daily Living, and the Hip Outcome Score—Sport-Specific Subscale obtained preoperatively and at 2 years' and 3 years' follow-up. Any complications, revision surgeries, and conversions to total hip arthroplasty were noted. **Results:** Of the patients, 54 (82%) were available for follow-up. The mean length of follow-up for this cohort was 2.4 years (range, 1.7 to 4.1 years). At final follow-up, there was significant improvement in all 4 patient-reported outcome scores (modified Harris Hip Score, 63.7 to 89.9; Non-Arthritic Hip Score, 60.9 to 87.9; Hip Outcome Score—Activities of Daily Living, 66.9 to 91.0; and Hip Outcome Score—Sport-Specific Subscale, 46.5 to 79.2) ($P < .0001$). A good or excellent result was achieved in 46 patients (85.2%). There was significant improvement in pain as measured by the change in visual analog scale score from 6.5 to 2.3 ($P < .0001$), and the patient satisfaction rating was 8.56 ± 2.01 . There were no perioperative complications. Revision surgery was required in 3 patients (5.6%), and 2 patients (3.7%) required conversion to total hip arthroplasty. **Conclusions:** The clinical results of this labral base repair technique showed favorable clinical improvements based on 4 patient-reported outcome questionnaires, visual analog scale, and patient satisfaction. More clinical, biomechanical, and histologic studies are needed to determine the optimal repair technique. **Level of Evidence:** Level IV, therapeutic case series.

The function of the acetabular labrum has been closely examined in the past decade with the progression of hip preservation surgery. The labrum functions to increase the volume of the acetabulum,¹ enhance hip stability, and act as a suction seal to maintain hydrostatic pressure of joint fluid, protecting articular cartilage.²⁻⁵ Seldes et al.¹ described 2 types of

labral tears based on histologic examination: type 1 tears involve the chondrolabral junction, and type 2 tears involve intrasubstance damage. The labrum often tears in the setting of femoroacetabular impingement (FAI), but tearing can also occur with instability and dysplasia, each with different pathomechanics.

In FAI, the labrum is torn from the abnormal abutment of the proximal femur against the acetabular rim.⁶ In pincer-type FAI, bone recontouring on the acetabular rim is performed and often the torn labrum is further destabilized and requires repair. This can occur with or without previous labral tearing. The role of labral repair in FAI has been delineated in several studies.⁷⁻¹⁰ Techniques for labral repair have been reported, typically with a circumferential vertical repair technique.

The senior author has previously described a technique whereby the labrum is repaired to the acetabular rim using sutures penetrating the substance of the labrum.¹¹ This suture configuration allows the free edge of the labrum to contact the femoral head

From the American Hip Institute (T.J.J., C.E.S., D.L., Y.F.E.B., B.G.D.), and Stritch School of Medicine, Loyola University (B.G.D.), Chicago, Illinois; Hinsdale Orthopaedics (C.E.S., B.G.D.), Hinsdale, Illinois; and Arthrex (B.H.), Naples, Florida, U.S.A.

The authors report the following potential conflict of interest or source of funding: B.H. is a salary paid employee of Arthrex and receives royalties for an orthopaedic product/device from Arthrex. B.G.D. receives support from MAKO Surgical and Arthrex.

Received January 31, 2013; accepted November 20, 2013.

Address correspondence to Benjamin G. Domb, M.D., Loyola University Chicago, Hinsdale Orthopaedics, American Hip Institute, 1010 Executive Ct, Ste 250, Westmont, IL 60559, U.S.A. E-mail: DrDomb@americanhipinstitute.org

© 2014 by the Arthroscopy Association of North America

0749-8063/1391/\$36.00

<http://dx.doi.org/10.1016/j.arthro.2013.11.021>

without any interposed suture on the femoral head articular cartilage. The theoretical advantage of this technique is that because less labral tissue is incorporated into the suture, the free edge of the labrum has a lower likelihood of elevating off of the femoral head, removing the suction-seal effect of the labrum. This is an observation made by the senior author. This technique was met with some controversy in the form of a letter to the editor that highlighted the already-reported good clinical outcomes reported with the looped stitch.^{8,12,13}

The purpose of this study was to evaluate the clinical outcomes of a cohort of patients with a minimum of 2 years' follow-up who underwent labral repair by a previously published labral base repair (LBR) suture technique for the treatment of pincer-type FAI. Our hypothesis was that patients who underwent labral repair with LBR would have postoperative improvement based on patient-reported outcome (PRO) scores.

Methods

At our institution, data are prospectively collected on all patients undergoing hip preservation surgery. The PRO scores include the modified Harris Hip Score (mHHS), the Non-Arthritic Hip Score (NAHS),¹⁴ the Hip Outcome Score—Activities of Daily Living (HOS-ADL), and the Hip Outcome Score—Sport-Specific Subscale (HOS-SSS)¹⁵ obtained preoperatively and at 2 years' and 3 years' follow-up. All 4 questionnaires are used because it has been reported that there is no conclusive evidence for the use of a single PRO questionnaire for patients undergoing hip arthroscopy.¹⁶ Any complications, revision surgeries, and conversions to total hip arthroplasty (THA) were noted.

During the study period from April 2008 to November 2010, patients who received hip arthroscopy for symptomatic FAI and underwent the previously described LBR technique were included in the study group. Patients with Tönnis arthritis grade 2 or greater or who have dysplasia are contraindicated for hip arthroscopy and thus are generally excluded. For the purpose of this study, patients with Legg-Calves-Perthes disease or who underwent simple looped stitch repair were excluded. This study was approved by our institutional review board.

Clinical Evaluation

All patients and radiographs were evaluated by the senior author (B.G.D.). Radiographs include standing and supine anteroposterior pelvis, false-profile, modified Dunn, and cross-table lateral views. Preoperative radiographs were assessed for signs of pincer impingement (crossover sign, coxa profunda), cam impingement (alpha angle $>50^\circ$), dysplasia (lateral center-edge angle $<20^\circ$), and Tönnis arthritis stage. Preoperative and

postoperative measurements of the lateral center-edge angle and alpha angle, on the Dunn view, were taken to assess acetabuloplasty and femoroplasty, respectively. All patients in this study had a magnetic resonance arthrogram obtained preoperatively for assessment of labral tearing and chondral damage.

Surgical Technique

All hip arthroscopies were performed by the senior author (B.G.D.) with patients in the modified supine position on a traction table with a well-padded perineal post. Access to the joint is performed as previously described¹⁷ using a standard anterolateral portal. An anterior portal is placed under direct visualization, and a modified midanterior portal is used for labral repair. The capsule is cut with a beaver blade parallel to the labrum, connecting the anterior and anterolateral portals and extending medially as needed to address all intra-articular pathology or for iliopsoas fractional lengthening. Routine diagnostic arthroscopy is performed, with assessment of the ligamentum teres, cartilage surfaces, and labrum. The labral tear type was diagnosed based on the Seldes classification, type 1 being a chondrolabral separation and type 2 being intrasubstance tearing.² Transitional zone cartilage was classified based on the ALAD (acetabular labral articular disruption) classification: type 1 is softening of the cartilage (wave sign), type 2 is early peel of the cartilage (carpet delamination), type 3 is a large flap of cartilage, and type 4 is missing cartilage.¹⁸ The capsule is elevated from the labrum by electrocautery with care taken to preserve the capsular tissue for later repair. Rim resection is performed with a 5.5-mm round burr, and labral takedown from the articular cartilage is performed in cases in which greater than 3 mm of rim will be removed. This is performed to remove the remaining cartilage that would become redundant after the bone resection. If a small rim resection is planned, the labrum is left attached to the cartilage and bone is resected with care taken not to damage the labrum. The amount of bone removed is determined based on preoperative and intraoperative fluoroscopy. If there is evidence of pincer impingement, an acetabuloplasty is performed and the amount is determined by the extent of crossover or depth of profunda. During rim resection, the bone removed lies beneath the cartilage and therefore the labrum is separated from the cartilage to remove the overlying cartilage. After this is completed, the labrum and rim are prepared for repair. Technical pearls are listed in [Table 1](#).

LBR Technique

Anchors are placed through a modified midanterior portal for the 2- to 5-o'clock position, through an anterolateral portal for the 12- to 2-o'clock position,

Table 1. Pearls for LBR

Perform careful capsule elevation to preserve labral tissue.
Use small-diameter suture passer through labrum.
Place anchors close to cartilage to prevent lifting labrum off femoral head.
Visualize starting point of anchor placement and then drill while monitoring articular surface for penetration.
Use disposable cannula for working portal.
Ensure that sufficient labral tissue is available and incorporated into suture.
Perform adequate resection of bony impingement lesions.

and through a posterolateral portal for the 10- to 12-o'clock position. The holes are drilled as close to the cartilage as possible without violating the cartilage itself, aiming for 2 mm from the edge. This is important to prevent lifting the labrum off of the femoral head. The entry point of the drill is visualized from the peripheral compartment looking down onto the acetabular rim, and then the arthroscope is positioned in the central compartment to view the acetabular cartilage surface to ensure there is no penetration of the articular cartilage while drilling. This is repeated for as many anchors as needed for stable repair, with anchors placed approximately 6 to 8 mm apart. It is our preferred technique to drill all holes necessary before suture passage and anchor placement. A partially threaded cannula is then placed for suture and anchor passage. The LBR stitch is passed by use of a SutureLasso (Arthrex, Naples, FL) to pierce the labrum, and a stiff nonabsorbable FiberStick suture (Arthrex) is passed through its base. A rigid suture is used so that this can be passed directly through the FiberStick rather than passing a wire and

exchanging for a suture. The direct passage of suture eliminates a step and saves time, which is important because this procedure is performed under traction. The narrow diameter of this instrument avoids splitting of the labrum, a potential pitfall when puncturing the labrum, especially with large bird-beak instruments. When the detached labrum is greater than 5 mm in thickness, the LBR is performed with a vertical mattress technique by passing the suture back through the base of the labrum. When the labrum is less than 5 mm in thickness, the mattress LBR technique is not recommended because the thinner labrum may not support the mattress-configuration labral base stitch. In this case the suture is passed around the labral base instead of back through the labrum (Fig 1). A knotless 2.9-mm PushLock suture anchor (Arthrex) is used to fix the suture to the acetabular rim. The labrum can be rotated into proper orientation by alternating tension on the sutures before anchor passage. These steps are repeated until all previously drilled holes are filled and the labrum has stable fixation. Once the labrum has been secured, traction is then released and the labrum is seen from the peripheral compartment in contact with the femoral head, re-creating the suction seal (Fig 2). The hip is then flexed, providing access to the peripheral compartment, and osteoplasty is performed when indicated.

Patients are placed in an X-Act ROM brace (DJO Global, Vista, CA) for 2 weeks and use crutches with toe-touch weight bearing for 2 weeks. Physical therapy is begun as early as postoperative day 1 with passive range of motion using either a continuous passive motion machine or stationary bicycle.

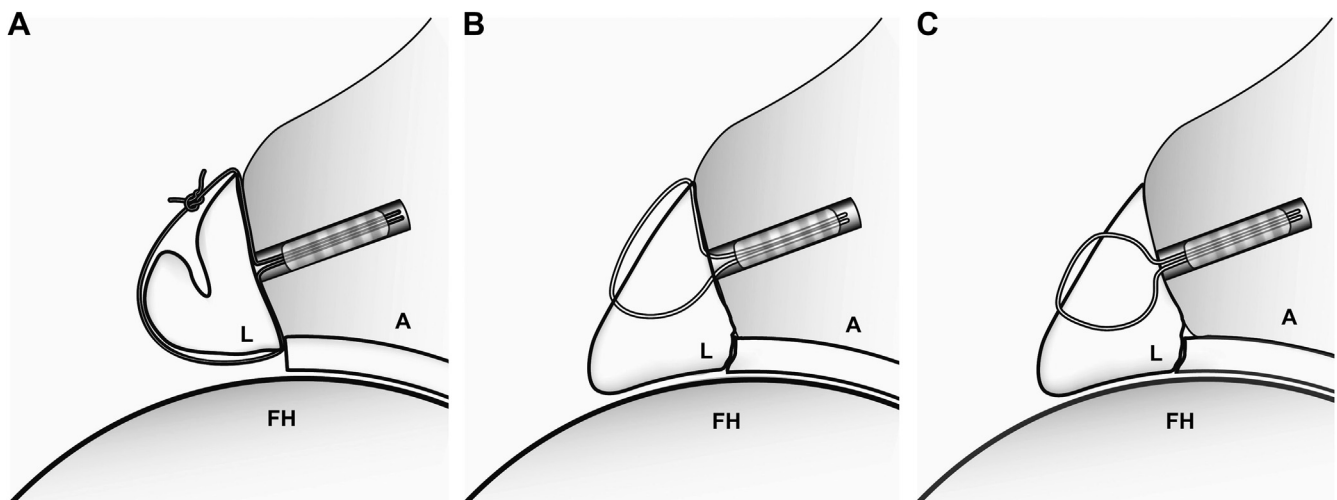


Fig 1. Diagram of previously described technique. (A, acetabulum; FH, femoral head; L, labrum.) (A) Labral repair with a simple looped stitch passed circumferentially around the labrum, with the potential to cause bunching of the labrum and disrupting the contact seal. (B) The labral base stitch (LBR) involves a single passage of suture through the base of the labrum, providing secure fixation of the labral base while preserving the free edge for contact with the femoral head, allowing the labrum to serve its function as a suction seal. (C) LBR with a vertical mattress technique involves 2 passes of the suture through the base of the labrum. This technique is recommended when the width of the labrum is at least 5 mm.

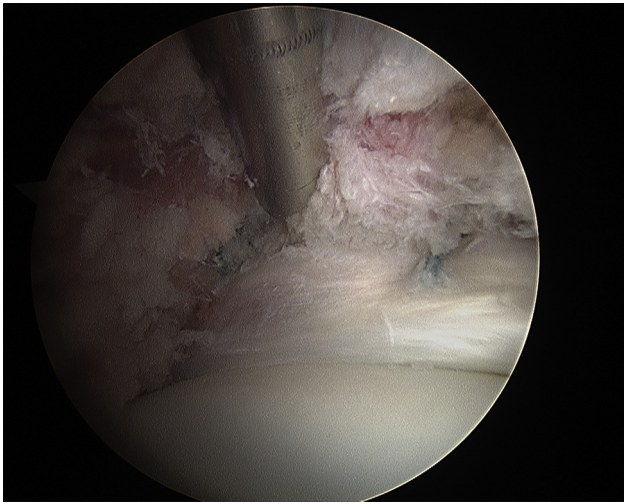


Fig 2. Arthroscopic photograph of anterosuperior labrum of right hip after LBR. This view from the peripheral compartment with traction off shows the free edge of the labrum resting on the femoral head, restoring the suction-seal function of the labrum.

Statistical Analysis

A 2-tailed paired *t* test was used to analyze changes in PRO scores (mHHS, NAHS, HOS-ADL, and HOS-SSS) and pain scores (visual analog scale [VAS]) from preoperatively to postoperatively. On the basis of previous studies,^{19,20} a power analysis was performed using a mean improvement in mHHS of 20 and an SD of 15. With power set at 0.8, 22 patients would be needed to have adequate power. $P < .05$ was considered statistically significant.

Results

During the study period, 66 patients met the inclusion criteria. Of these patients, 54 (82%) were available for follow-up. The mean age was 28.8 ± 12.8 years (range, 14 to 57 years). One patient had a prior hip arthroscopy at an outside institution and underwent revision because of continued hip pain from unaddressed FAI, whereas all others underwent primary hip arthroscopy. The mean length of follow-up for this cohort was 2.4 ± 0.58 years (range, 1.7 to 4.1 years). Patient demographic data are presented in Table 2.

Findings at the time of surgery are detailed in Table 3. All patients had a labral tear, 36 had cartilage damage at the chondrolabral junction, and 10 had ligamentum teres tears. All patients underwent labral repair by the previously described technique. Other procedures included femoral osteoplasty in 34 patients, chondroplasty in 44, and ligamentum teres debridement in 10 (Table 4).

At final follow-up, there was significant improvement in all PRO scores (mHHS, NAHS, HOS-ADL, and HOS-SSS) ($P < .0001$) (Table 5). The mHHS improved by 25.5 points, the NAHS improved by 27.3 points, the

Table 2. Patient Demographic Data for Cohort Receiving LBR (n = 54)

Category	Data
Gender [n (%)]	
Female	34 (63)
Male	20 (37)
Side [n (%)]	
Right	28 (52)
Left	26 (48)
Revision [n (%)]	1 (1.8)
Workers' Compensation [n (%)]	3 (5.5)
Impingement [n (%)]	
Isolated cam	3 (5.5)
Isolated pincer	19 (35)
Combined	32 (59)
Mean age (range) (yr)	28.81 (14-57)

HOS-ADL improved by 23.2 points, and the HOS-SSS improved by 32.6 points. The VAS pain score had a significant improvement from 6.5 to 2.3 ($P < .0001$). The patient satisfaction rating was 8.6, with 48 patients (88.8%) reporting a satisfaction rating of 7 or greater. On the basis of the mHHS, 46 patients (85.2%) achieved a good or excellent result. There were no perioperative complications. Overall, 3 patients (5.6%) required revision surgery and 2 (3.7%) required conversion to THA at a mean of 18 months after arthroscopy. The previous labral repair was healed in all 3 revision cases. One patient underwent revision for heterotopic ossification excision, and the other 2 underwent revision for recurrent pain after arthroscopy. Intraoperative findings for the latter 2 patients showed adhesions and cartilage defects that were treated with chondroplasty. The patients who required THA were aged 48 and 53 years; 1 had dysplasia, and the other patient was a Workers' Compensation patient. The 3 revision arthroscopies were performed at a mean of 677 days postoperatively (range, 322 to 1,048 days). Two patients ultimately achieved an excellent outcome after revision, whereas 1 patient had a poor outcome at final follow-up.

Table 3. Operative Findings for Labrum and Articular Cartilage

	No. of Patients
Labral tear (Seldes classification)	
1	32
2	8
Combined	14
Total	54
Cartilage (ALAD classification ¹⁸)	
0	18
1	10
2	16
3	9
4	1
Total	54

ALAD, acetabular labral articular disruption.

Table 4. Associated Procedures Performed at Time of Labral Repair

	No. of Procedures (%)
Acetabuloplasty	51 (94)
Iliopsoas release	19 (35)
Chondroplasty	44 (81)
Ligamentum teres debridement	10 (19)
Osteoplasty	34 (63)
Capsule plication	26 (48)
Capsule release	28 (52)
Loose body removal	7 (13)
Trochanteric bursa debridement	3 (5.5)
Gluteus medius repair	1 (1.9)
Microfracture	0

For patients who underwent acetabuloplasty, the lateral center-edge angle decreased from $29.4^\circ \pm 5.8^\circ$ to $27.3^\circ \pm 5.9^\circ$ ($P = .0002$). For patients who had femoroplasty, the alpha angle decreased from $61.3^\circ \pm 11.5^\circ$ to $44.8^\circ \pm 7.3^\circ$ ($P < .0001$).

Discussion

Arthroscopic labral repair by the described LBR technique has been shown to be a successful technique for labral repair based on the PROs reported in this study. This technique generated a response from advocates of the looped stitch technique when initially published.¹² Although the benefits of labral repair continue to be shown,⁷⁻¹⁰ on the basis of current clinical outcomes research, the specific technique most optimal for repair remains to be determined. The theoretical benefit of LBR is incorporation of only the base of the labrum, allowing the free edge to be in contact with the femoral head. In addition, by not looping a suture around the entire labrum, the procedure is less likely to lift the labrum up onto the acetabular rim and off of the femoral head. This would then eliminate the suction-seal function of the labrum.⁴

Similar to joints such as the shoulder and knee for which the aim is anatomic reconstruction, the objective of the described technique is to restore the anatomy of the labrum. Theoretically, by restoring the anatomy of the labrum, the function of the labrum can be restored. A repair in which the labrum is lifted off of the head does not restore the optimal function of the labrum.

Table 5. Preoperative and Postoperative PRO, VAS, and Patient Satisfaction Scores

	Preoperative (Mean \pm SD)	Postoperative (Mean \pm SD)	Significance
mHHS	63.7 \pm 17.9	89.9 \pm 13.0	$P < .00001$
HOS-ADL	66.9 \pm 21.2	91.0 \pm 14.4	$P < .00001$
HOS-SSS	46.5 \pm 24.8	79.2 \pm 25.4	$P < .00001$
NAHS	60.9 \pm 21.1	87.9 \pm 15.7	$P < .00001$
VAS	6.5 \pm 2.2	2.3 \pm 2.3	$P < .00001$
Satisfaction		8.6 \pm 2.0	

A benefit of the LBR technique lies in the ability to protect against lifting the labrum from the femoral head. By incorporating only the base of the labrum, the remainder of the labrum is free to maintain its close approximation to the head while not lifting the entire labrum off of the head in the case of a misplaced anchor or over-tensioned suture.

The postoperative improvement after labral repair in our cohort is similar to most studies on labral repair.⁷⁻¹⁰ Larson and Giveans⁷ showed a significantly improved mHHS, Short Form 12 score, and VAS score in patients treated with labral repair versus labral debridement at a mean of 3.5 years, with the labral repair cohort scoring 94.3 on the mHHS. More recently, Krych et al.¹⁰ performed a prospective, randomized study with 18 patients undergoing labral repair and 18 patients undergoing limited debridement after rim trimming. The repair group showed a significantly higher mean HOS-ADL at a mean of 32 months' follow-up, with a mean score of 91.2, which is comparable to our cohort's score of 91.0. The improvement seen in our results, as well as the previous studies, is substantial and is a testament to the benefits of labral repair. The clinical benefit of LBR versus looped suture fixation is unknown and will be very difficult to elucidate because there are a multitude of confounding variables.

The strengths of this study include the large cohort of patients with a mean follow-up greater than 2 years using 4 PROs. The 4 PRO scores are an invaluable tool for measuring clinical outcomes.^{16,21} The use of multiple scoring systems as well as the more simple patient satisfaction rating and VAS score allows researchers to look for consistency in patient reporting, as well as overcome ceiling effects that can occur.

Limitations

A limitation to this study is the lack of a comparison group. Our aim was to show the safety and efficacy of a previously published technique, not to compare labral repair with labral debridement or with other means of labral repair. Future studies could perhaps aim to match groups based on suture configuration; however, this will also be limited by other variables such as associated procedures. Associated procedures do create additional variables that make the suture technique difficult to isolate as a cause for clinical outcomes. Very rarely is the exact same procedure performed in each hip. Just as each hip has very different morphology (e.g., cam/pincer impingement, labral tear location, instability, femoral version, snapping, or peritrochanteric disorders), each hip receives different treatment. This is a limitation of research that is inherent to clinical outcomes studies, specifically hip arthroscopy. Postoperative imaging is paramount to assessing surgical techniques. We did not evaluate labral healing with postoperative magnetic resonance imaging (MRI). The

efficacy of MRI after labral repair is of questionable use because postoperative changes confound the results of MRI after hip arthroscopy.²² The most useful results regarding healing were shown in the 3 revision cases that had excellent healing of the labrum, even at the chondrolabral junction.

Conclusions

The clinical results of the described LBR technique showed favorable clinical improvements based on 4 PRO questionnaires, the VAS, and patient satisfaction. More clinical, biomechanical, and histologic studies are needed to determine the optimal repair technique.

References

1. Seldes R, Tan V, Hunt J, Katz M, Winiarsky R, Fitzgerald R. Anatomy, histologic features and vascularity of the adult acetabular labrum. *Clin Orthop Relat Res* 2001;283:232-240.
2. Safran M, Giordano G, Lindsey D, et al. Strains across the acetabular labrum during hip motion. A cadaveric model. *Am J Sports Med* 2011;39(suppl):92S-102S.
3. Smith M, Panchal H, Thiele R, Sekiya J. Effect of acetabular labrum tears on hip stability and labral strain in a joint compression model. *Am J Sports Med* 2011;39(suppl):103S-110S.
4. Ferguson SJ, Bryant JT, Ganz R, Ito K. An in vitro investigation of the acetabular labral seal in hip joint mechanics. *J Biomech* 2003;36:171-178.
5. Ferguson SJ, Bryant JT, Ganz R, Ito K. The influence of the acetabular labrum on hip joint cartilage consolidation: A poroelastic finite element model. *J Biomech* 2000;33:953-960.
6. Ganz R, Parvizi J, Beck M, Leunig M, Nötzli H, Siebenrock KA. Femoroacetabular impingement: A cause for osteoarthritis of the hip. *Clin Orthop Relat Res* 2003;417:112-120.
7. Larson C, Giveans R. Arthroscopic debridement versus refixation of the acetabular labrum associated with femoroacetabular impingement. *Arthroscopy* 2009;25:369-376.
8. Philippon M, Weiss D, Kuppersmith D, Briggs K, Hay C. Arthroscopic labral repair and treatment of femoroacetabular impingement in professional hockey players. *Am J Sports Med* 2010;38:99-104.
9. Kelly BT, Weiland DE, Schenker ML, Philippon MJ. Arthroscopic labral repair in the hip: Surgical technique and review of the literature. *Arthroscopy* 2005;21:1496-1504.
10. Krych AJ, Thompson M, Knutson Z, Scoon J, Coleman SH. Arthroscopic labral repair versus selective labral debridement in female patients with femoroacetabular impingement: A prospective randomized study. *Arthroscopy* 2013;29:46-53.
11. Fry R, Domb B. Labral base refixation in the hip: Rationale and technique for an anatomic approach to labral repair. *Arthroscopy* 2010;26:S81-S89.
12. Lertwanich P, Eijnisman L, Philippon MJ. Comments on "Labral base refixation in the hip: Rationale and technique for an anatomic approach to labral repair." *Arthroscopy* 2011;27:303-304.
13. Philippon MJ, Briggs KK, Yen YM, Kuppersmith DA. Outcomes following hip arthroscopy for femoroacetabular impingement with associated chondrolabral dysfunction: Minimum two-year follow-up. *J Bone Joint Surg Br* 2009;91:16-23.
14. Christensen CP, Althausen PL, Mittleman MA, Lee JA, McCarthy JC. The nonarthritic hip score: Reliable and validated. *Clin Orthop Relat Res* 2003;406:75-83.
15. Martin RL, Philippon MJ. Evidence of validity for the hip outcome score in hip arthroscopy. *Arthroscopy* 2007;23:822-826.
16. Tijssen M, vanCingel R, van Melick N, Visser E. Patient-reported outcome questionnaires for hip arthroscopy: A systematic review of the psychometric evidence. *BMC Musculoskelet Disord* 2011;12:117.
17. Domb B, Hanypsiak B, Botser I. Labral penetration rate in a consecutive series of 300 hip arthroscopies. *Am J Sports Med* 2012;40:864-869.
18. Callaghan JJ, Rosenberg AG, Rubash HE, eds. *The adult hip*. Philadelphia: Lippincott Williams & Wilkins, 2007.
19. Byrd JW, Jones KS. Arthroscopic management of femoroacetabular impingement in athletes. *Am J Sports Med* 2011;39:7S-13S.
20. Nho S, Magennis E, Singh C, Kelly B. Outcomes after the arthroscopic treatment of femoroacetabular impingement in a mixed group of high-level athletes. *Am J Sports Med* 2011;39:14S-19S.
21. Lodhia P, Slobogean GP, Noonan VK, Gilbert MK. Patient-reported outcome instruments for femoroacetabular impingement and hip labral pathology: A systematic review of the clinimetric evidence. *Arthroscopy* 2011;27:279-286.
22. McCarthy JC, Glassner PJ. Correlation of magnetic resonance arthrography with revision hip arthroscopy. *Clin Orthop Relat Res* 2013;471:4006-4011.