

Hips With Acetabular Retroversion Can Be Safely Treated With Advanced Arthroscopic Techniques Without Anteverting Periacetabular Osteotomy

Midterm Outcomes With Propensity-Matched Control Group

David R. Maldonado,* MD, Jeffery W. Chen,[†] BA, Cynthia Kyin,* BA, Philip J. Rosinsky,* MD, Jacob Shapira,* MD, Jarod M. Karom,* BA, Ajay C. Lall,* MD, MS, and Benjamin G. Domb,*[‡] MD
Investigation performed at the American Hip Institute Research Foundation, Des Plaines, Illinois, USA

Background: Different options, from reverse (anteverting) periacetabular osteotomy to hip arthroscopy, have been proposed for surgical treatment of femoroacetabular impingement syndrome (FAIS) in the setting of acetabular retroversion.

Purpose: (1) To report and analyze midterm patient-reported outcome scores (PROs) in patients with FAIS and labral tears in the setting of acetabular retroversion after isolated hip arthroscopy and (2) to compare these PROs with those of a propensity-matched control group without acetabular retroversion.

Study Design: Cohort study; Level of evidence, 3.

Methods: Prospectively collected data were retrospectively reviewed for patients who underwent hip arthroscopy for FAIS and labral tear treatment between June 2008 and March 2014. Inclusion criteria were as follows: acetabular retroversion, pre- and postoperative PROs for modified Harris Hip Score (mHHS), Non-arthritic Hip Score, Hip Outcome Score–Sports Specific Scale (HOS–SSS), and visual analog scale (VAS). Propensity score matching was utilized to identify a control group without acetabular retroversion matched 1:1 with similar age, sex, body mass index, acetabular and femoral head Outerbridge grade, preoperative lateral center-edge angle, and labral treatment. Patient acceptable symptomatic state (PASS) and/or minimal clinically important difference (MCID) for the mHHS, HOS–SSS, International Hip Outcome Tool–12, and VAS was calculated.

Results: A total of 205 hips with acetabular retroversion were matched to a control group. The groups showed no difference in demographic variables. The retroversion group was composed of 139 female and 66 male hips, with a mean \pm SD age of 23.81 ± 7.28 years and follow-up time of 65.24 ± 20.31 months. Intraoperative diagnostic data and procedures performed were similar between groups, except more femoroplasties were performed in the retroversion group. Significant improvements for the mHHS, Non-arthritic Hip Score, HOS–SSS, and VAS were seen for both groups at a mean 5-year follow-up. The proportion of patients who reached the PASS and MCID were similar.

Conclusion: In the setting of FAIS and labral tears, patients with acetabular retroversion can be safely treated with advanced hip arthroscopic techniques without reverse (anteverting) periacetabular osteotomy in a high-volume surgeon's hands. Patients with acetabular retroversion demonstrated favorable PROs at midterm follow-up. Furthermore, the proportion of patients reaching the MCID and PASS for several PROs were comparable with those of a propensity-matched control group without acetabular retroversion.

Keywords: hip arthroscopy; acetabular retroversion; outcomes; femoroacetabular impingement

Global acetabular retroversion is characterized by anterolateral acetabular overcoverage that may lead to impingement and can coexist with dysplasia.⁶⁷ Reverse (anteverting) periacetabular osteotomy (rPAO) has been

the gold standard for surgical treatment in patients with retroverted acetabula, with or without dysplasia, with good results at short- and midterm follow-up.^{53,64,66} Nevertheless, in cases of acetabular retroversion without severe dysplasia, a minimally invasive approach with hip arthroscopy has been proposed as an alternative that can achieve favorable outcomes and results in the short term.²⁷ Potential benefits of hip arthroscopic management include less morbidity and the ability to assess and treat intra-articular

pathologies.^{39,61} Posterior wall deficiency (undercoverage) is one of the structural characteristics of acetabular retroversion, and the addition of arthroscopic anterolateral rim trimming brings the concern for potential iatrogenic instability.^{55,68}

The purposes of the current study were to (1) report and analyze midterm patient-reported outcome (PRO) scores in patients with femoroacetabular impingement syndrome (FAIS) and labral tear in the setting of acetabular retroversion after isolated hip arthroscopy and (2) compare these PROs with a propensity-matched control group without acetabular retroversion.

It was hypothesized that after hip arthroscopy without rPAO, patients with acetabular retroversion would experience significant and favorable PROs at midterm follow-up and that midterm PROs in this group would be comparable with those of a propensity-matched control group without acetabular retroversion.

METHODS

Patient Selection

Prospectively collected as part of the American Hip Institute Hip Preservation Registry, data were retrospectively reviewed for patients who underwent hip arthroscopy between June 2008 and March 2014. All patients aged ≤ 40 years were considered eligible if they received primary arthroscopic treatment for labral tears and FAIS during this period. Acetabular retroversion was defined radiographically in the supine anteroposterior (AP) pelvis view by the presence of acetabular crossover $>20\%$, the presence of ischial spine sign, and posterior wall sign (Figure 1).²⁷ Patients were included if they had pre- and postoperative PROs for the following outcome measures: modified Harris Hip Score (mHHS),¹ Non-arthritic Hip Score (NAHS),¹² Hip Outcome Score–Sports Specific Scale (HOS-SSS),⁴⁴ and visual analog scale (VAS).⁹ Patients were excluded from analysis if they had Tönnis grade osteoarthritis ≥ 2 or a diagnosed ipsilateral hip condition, such as avascular necrosis, Legg-Calvé-Perthes disease, hip dysplasia (lateral center-edge angle [LCEA] $\leq 18^\circ$),⁴⁶

or slipped capital femoral epiphysis. Patients with workers' compensation status or those who underwent previous hip surgery were also excluded from the study.

Participation in the American Hip Institute Hip Preservation Registry

While the present study represents a unique analysis, data on some patients may have been reported in other studies. All data collection received institutional review board approval.^{27,34}

Physical Examination

All patients underwent a physical examination by the senior author (B.G.D.) pre- and postoperatively. This examination assessed range of motion, gait, alignment, and strength. Impingement testing was used to assess FAIS. Specifically, the anterior impingement test put the hip through forced flexion, adduction, and internal rotation. The lateral impingement test put the hip through forced abduction and external rotation, and the posterior impingement test put the hip through extension, followed by external rotation.¹⁴ The Trendelenburg test was used to assess abductor function⁷¹ and the Beighton test for ligamentous laxity.^{42,62}

Radiographic Imaging

A series of radiographic images were obtained on all patients before surgery, which included the following views: supine AP, modified 45° Dunn, and false profile.^{13,21,48,69} Evaluations of these images were performed with General Electric Healthcare's Picture Archiving and Communication System. The institution's radiographic measurements have demonstrated good interobserver reliability in previous studies.^{20,27,34,60}

The supine AP pelvis view was used to measure the extent of osteoarthritis according to Tönnis grade, ischial spine sign, crossover sign, posterior wall sign, acetabular inclination, LCEA, and 3 measures of joint space (lateral, central, and medial sourcil).^{3,13,18,30,31} The anterior

‡Address correspondence to Benjamin G. Domb, MD, American Hip Institute, 999 E Touhy Ave, Suite 450, Des Plaines, IL 60018, USA (email: DrDomb@americanhipinstitute.org).

*American Hip Institute, Des Plaines, Illinois, USA.

†School of Medicine, Vanderbilt University, Nashville, Tennessee, USA.

Submitted October 10, 2019; accepted February 17, 2020.

One or more of the authors has declared the following potential conflict of interest or source of funding: B.G.D. has had ownership interests in Hinsdale Orthopaedics, the American Hip Institute, SCD#3, North Shore Surgical Suites, and Munster Specialty Surgery Center; has received research support from Arthrex, ATI, the Kauffman Foundation, Stryker, and Pacira Pharmaceuticals; has received consulting fees from Adventist Hinsdale Hospital, Arthrex, MAKO Surgical, Medacta, Pacira Pharmaceuticals, and Stryker; has received educational support from Arthrex, Breg, and Medwest; has received speaking fees from Arthrex and Pacira Pharmaceuticals; and receives royalties from Arthrex, DJO Global, MAKO Surgical, Stryker, and Orthomerica. B.G.D. is the medical director of hip preservation at St Alexius Medical Center and a board member for the American Hip Institute Research Foundation, AANA Learning Center Committee, the *Journal of Hip Preservation Surgery*, and the *Journal of Arthroscopy*. The American Hip Institute Research Foundation funds research and is where our study was performed. A.C.L. reports educational support from Medwest and Smith & Nephew; research support from Arthrex and Stryker; food and beverage from Smith & Nephew, Stryker, Zimmer Biomet, and Arthrex; travel and lodging from Stryker and Arthrex; and consulting fees from Arthrex and Graymont Medical. D.R.M. reports food/beverage and travel/lodging support from Arthrex, Stryker, and Smith & Nephew and is a board member of the *Journal of Arthroscopy*. J.S. reports food/beverage and travel/lodging support from Arthrex, Stryker, and Smith & Nephew. P.J.R. reports food/beverage and travel/lodging support from Arthrex, Stryker, and Smith & Nephew. AOSSM checks author disclosures against the Open Payments Database (OPD). AOSSM has not conducted an independent investigation on the OPD and disclaims any liability or responsibility relating thereto.

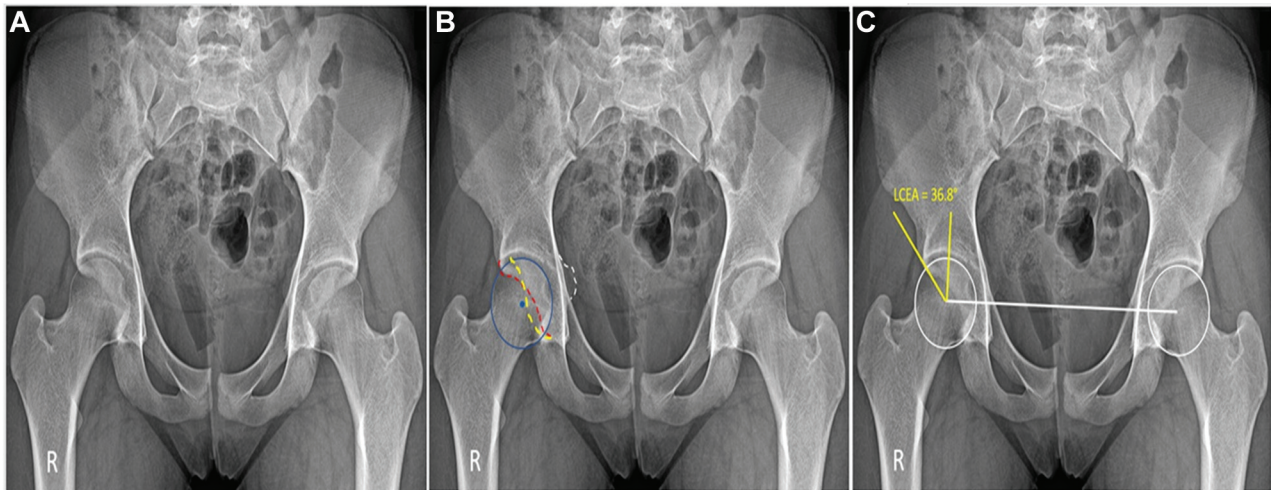


Figure 1. Radiographic assessment of acetabular retroversion in the supine anteroposterior pelvis view. All images correspond to the same patient. R, right hip. (A) Supine anteroposterior pelvis view. (B) Red dotted line, anterior acetabular wall; yellow dotted line, posterior acetabular wall. Intersection between the walls indicate a positive crossover sign. Blue dot, center of the femoral head lateral to the posterior wall (positive wall sign); white dotted line, positive ischial spine sign. (C) LCEA (lateral center-edge angle) was measured.

center-edge angle, a measure of acetabular anterior coverage, was determined from the false-profile view.³³ The modified 45° Dunn view was used to measure alpha angle and head-neck offset to quantify cam impingement, defined as alpha angle >55° or offset <0.8 cm.^{26,41} Additionally, labral tears and other potential extra- and intra-articular defects were determined with magnetic resonance arthrography for all patients.

Surgical Indication and Technique

Patients were indicated for arthroscopic surgery if their radiographic imaging, history, and physical examination demonstrated evidence of symptomatic FAIS and labral tears; if they experienced moderate to severe pain that was unresponsive to at least 3 months of nonsurgical treatment, including physical therapy, nonsteroidal anti-inflammatory medication, and activity modification; and if no evidence of advanced arthritis based on preoperative diagnostic imaging was found.^{5,24}

Careful surgical indications and planning were completed in patients with acetabular retroversion (Table 1). Attention was paid to preoperative ranges of motion, bony anatomy, and location of chondrolabral damage.²⁷

All hip arthroscopies were performed by the senior author. Patients received general anesthesia and were placed in the modified supine position with a well-padded perineal post.³² Traction was applied and the hip joint vented under fluoroscopy.^{16,36} After placement of the anterolateral and midanterior portals and connection by an interportal capsulotomy, a diagnostic arthroscopy of the central compartment was performed to assess the labrum, intra-articular cartilage, and ligamentum teres. Labral

TABLE 1

Indications and Contraindications for Isolated Arthroscopic Treatment of Femoroacetabular Impingement Syndrome, Labral Tear, and Acetabular Retroversion^a

Indications	Contraindications
No evidence of severe chondral damage evidence on dGEMRIC	LCEA <18°
dGEMRIC indices indicating acceptable cartilage health	Advanced osteoarthritis, Tönnis grade ≥2

^adGEMRIC, delayed gadolinium-enhanced magnetic resonance imaging of cartilage; LCEA, lateral center edge angle.

tears were classified according to Seldes et al.⁶³ The chondrolabral junction was graded by the acetabular labrum articular disruption, and the acetabular or femoral head chondral damage was recorded per the Outerbridge classifications.^{45,52} Ligamentum teres damage was graded by the Domb and Villar classifications.^{4,23}

Various procedures were carried out according to a patient's intra-articular and peritrochanteric damage. Acetabuloplasty and femoral osteoplasty were performed under fluoroscopic guidance to treat anterolateral overcoverage and cam deformity, respectively.^{50,59} The comprehensive method for acetabular bone resection in the setting of retroversion was published elsewhere; nonetheless, an LCEA between 30° and 35° was the goal.^{15,27} Resection of cam deformity was completed with the goal of re-creating appropriate head-neck offset, spherical contour of the femoral head, and impingement-free range of motion.⁴¹

TABLE 2
Pearls and Pitfalls for Isolated Arthroscopic Treatment of Femoroacetabular Impingement Syndrome, Labral Tear, and Acetabular Retroversion

Pearls	Pitfalls
Only judicious anterolateral acetabular trimming	Minimal experience in advanced arthroscopy techniques may result in a nonreproducible procedure
Minimal acetabular trimming with care to avoid significant decrease in acetabular volume	Excessive acetabular rim trimming
Restoration of labral anatomy and function	Creation of a low-volume acetabulum causing increased load per unit area of cartilage
Preservation of the capsule for further capsular plication	Inadequate femoral cam correction

Based on the extent of tearing, labral size, and labral characteristics, labral tears were debrided, repaired, or reconstructed.^{11,19,38} Labral repairs were conducted through either a simple loop or a base refixation technique.²⁹ For labral reconstruction, a segmental technique with either auto- or allograft was used.^{8,38,58} Ligamentum teres injuries were debrided with a radiofrequency device and shaver.⁴⁰ Iliopsoas fractional lengthening was performed on patients with painful internal snapping hip syndrome.³⁷ The capsule was plicated; however, in surgical procedures before 2009, capsular plication was not yet performed in a routine fashion.¹⁰

Table 2 presents the pearls and pitfalls for arthroscopic treatment of acetabular retroversion.

Rehabilitation Protocol

The postoperative protocol was tailored to the specific procedures performed. All patients wore braces for stability (DJO Global) and were limited to 20 lb of flat-foot weight-bearing activity with crutches for at least 2 weeks. A stationary bike was used daily for 8 weeks postoperatively. Physical therapy began as early as 1 day after surgery.

Surgical Outcome Tools

Patients completed the mHHS, NAHS, HOS-SSS, and VAS outcome questionnaires preoperatively within a month of their surgery and postoperatively at 3 months, 1 year, and annually thereafter. Outcomes were recorded at clinical visits, through encrypted email, or by telephone interviews. Postoperative patient satisfaction on a scale from 0 to 10 and surgical complications were also recorded. The percentage of patients achieving the patient acceptable symptomatic state (PASS) for the mHHS (≥ 74 points) and minimal clinically important difference (MCID) for the mHHS ($\Delta \geq 8$ points) was calculated.⁶ The PASS (≥ 65 points) and MCID ($\Delta \geq 6$ points) were also found for the HOS-SSS,⁶ as were the PASS of the International Hip Outcome Tool–12 (iHOT-12; ≥ 63 points)⁴⁹ and the MCID of the VAS ($\Delta \leq -1.5$ points).⁴³ Postoperative iHOT-12, Veterans RAND 12-Item Health Survey (VR-12), and 12-Item Short

Form Health Survey (SF-12) questionnaires were implemented at the end of the study period. Rates of secondary surgical procedures, such as secondary arthroscopy and conversion to total hip arthroplasty (THA), were recorded for patients at 5-year and latest follow-up.

Statistical Analysis and Matching Process

Patients were matched on the logit of the propensity score via a nearest-neighbor (Euclidean distance) match algorithm. Matching was performed without replacement, and a caliper was set to 0.4 of the SD to restrict the donor pool. The covariates selected for included age at surgery, body mass index (BMI), acetabular and femoral head Outerbridge grade, preoperative LCEA, and labral treatment.^{2,28} Descriptive statistics were reported for demographic data, procedures performed, and PROs. A statistical significance was considered as $P < .05$. For continuous variables, normal distribution and equal variance were assessed with the Shapiro-Wilk test and F test. Normally distributed data with equal variance were analyzed with a 2-tailed t test, whereas nonparametric data were compared with the Wilcoxon signed rank or Mann-Whitney test, depending on the size of the samples. An a priori power analysis was calculated to find the number of patients necessary in each group to detect 80% power with a 1:1 matching ratio. Based on an expected mean difference in the mHHS of 8 points, the power analysis determined that 55 patients would be required for each group.⁵⁴ A chi-square or Fisher exact test was used for all categorical variables. This statistical analysis was performed with Python (v 3.7) and R Software (v 3.6.0).

RESULTS

Patient Demographics

During the study period, 681 patients satisfied the inclusion criteria, of which 666 had an mean 5-year follow-up (89.19%).²⁷ The patient selection flowchart is depicted in Figure 2. Of the 666 hips (517 patients), 205 had acetabular retroversion by preoperative radiograph. All 205 hips were matched 1:1 to control patients without acetabular retroversion. Patient data are presented in Table 3. The matched groups showed no difference in demographic variables ($P > .05$). The retroversion group was composed of 139 female hips and 66 male hips, with mean \pm SD age, BMI, and follow-up time being 23.81 ± 7.28 years, 23.89 ± 4.44 kg/m², and 65.24 ± 20.31 months.

Intraoperative Findings and Procedures

Intraoperative diagnostic data (Table 4) demonstrated no difference between groups in labral tear type, acetabular or femoral head cartilage damage, or ligamentum teres injuries ($P > .05$). The frequencies of treatments performed between groups were similar, except for femoroplasties ($P = .003$) (Table 5).

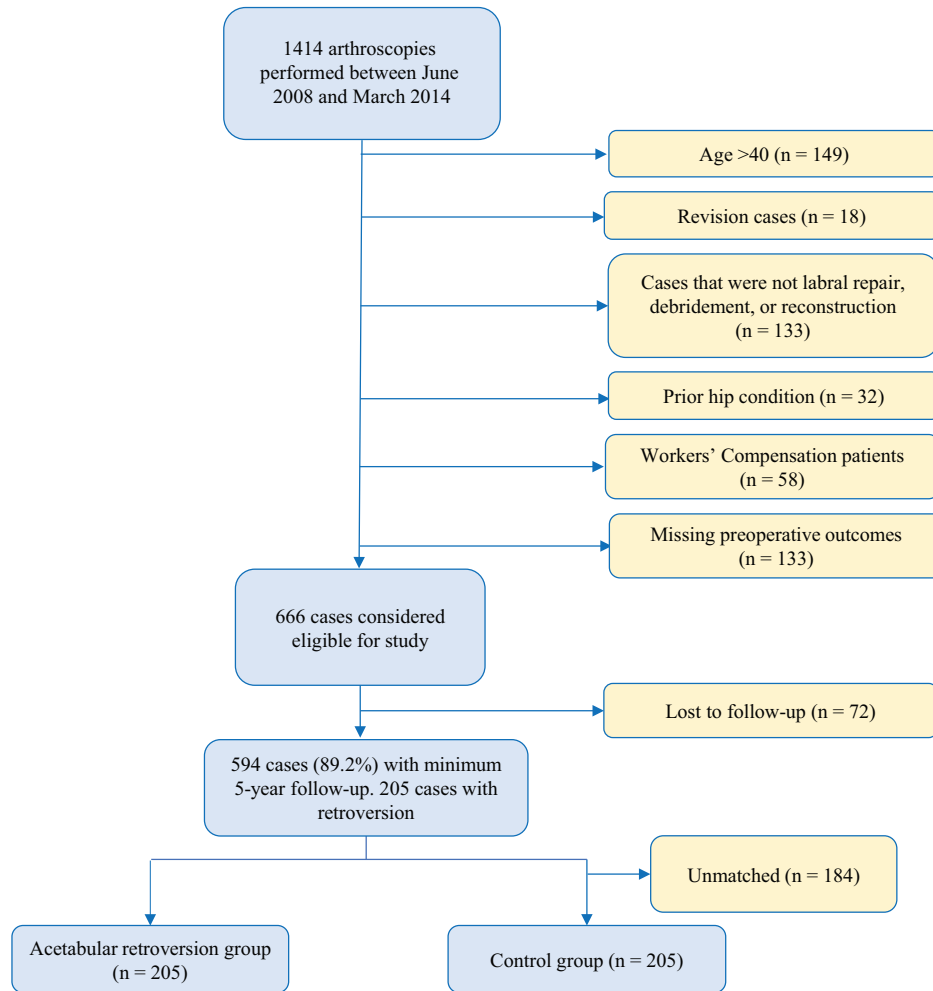


Figure 2. Patient selection flowchart.

TABLE 3
 Characteristics of Acetabular Retroversion and Control Groups^a

	Retroversion	Control	P Value
Hips included in study			
Left	107 (52.2)	96 (46.8)	.323
Right	98 (47.8)	109 (53.2)	
Sex			
Female	139 (67.8)	128 (62.4)	.300
Male	66 (32.2)	77 (37.6)	
Age at surgery, y	23.81 ± 7.28 (22.81-24.81)	24.61 ± 7.60 (23.56-25.66)	.351
BMI, kg/m ²	23.89 ± 4.44 (23.27-24.50)	23.98 ± 4.73 (23.33-24.64)	.903
Follow-up time, mo	65.24 ± 20.31 (62.44-68.04)	65.61 ± 17.83 (63.15-68.06)	.554

^aValues are presented as No. (%) or mean ± SD (95% CI). BMI, body mass index.

Radiographic Findings

There were no significant differences between the retroverted and control groups in any pre- or postoperative radiographic measurement (Table 6). There were significant

pre- to postoperative changes for LCEA and alpha angle for the control group, while for the retroversion group there were significant changes for LCEA, acetabular index, anterior center-edge angle, and alpha angle.

TABLE 4
Intraoperative Findings per Group^a

	Hips, No. (%)		P Value
	Retroversion	Control	
Seldes: labral tear type			.101
I	114 (55.6)	96 (46.8)	
II	39 (19)	56 (27.3)	
I and II	52 (25.4)	53 (25.9)	
ALAD			.850
0	23 (11.2)	28 (13.7)	
1	89 (43.4)	79 (38.5)	
2	50 (24.4)	50 (24.4)	
3	37 (18)	41 (20)	
4	6 (2.9)	7 (3.4)	
Outerbridge: acetabulum			.819
0	17 (8.3)	22 (10.7)	
1	93 (45.4)	84 (41)	
2	53 (25.9)	51 (24.9)	
3	33 (16.1)	38 (18.5)	
4	9 (4.4)	10 (4.9)	
Outerbridge: femoral head			.260
0	184 (89.8)	191 (93.2)	
1	3 (1.5)	1 (0.5)	
2	8 (3.9)	4 (2)	
3	4 (2)	7 (3.4)	
4	6 (2.9)	2 (1)	
LT percentile class: Domb			.139
0%	132 (64.4)	124 (60.5)	
>0% to <50%	50 (24.4)	56 (27.3)	
50% to <100%	22 (10.7)	18 (8.8)	
100%	1 (0.5)	7 (3.4)	
LT Villar class			.134
No tear	135 (65.9)	123 (60)	
Complete tear	2 (1)	9 (4.4)	
Partial tear	65 (31.7)	68 (33.2)	
Degenerative tear	3 (1.5)	5 (2.4)	

^aALAD, acetabular labral articular disruption; LT, ligamentum teres.

Surgical Outcomes

The PROs measured pre- and postoperatively are presented in Table 7. Both groups saw a significant increase in PROs from presurgery to the latest follow-up. The mean mHHS, NAHS, and HOS-SSS scores for the acetabular retroversion group increased by 22.04, 22.12, and 30.59 points, respectively ($P < .001$). The VAS scores decreased by 3.54 ($P < .001$). Similar findings were found for the control group. Across all recorded postoperative scores, no differences were found between groups. As shown in Table 8, 156 (76.1%) patients in the retroversion group reported improvement that met the threshold for the MCID, and 167 (81.5%) achieved the PASS for the mHHS questionnaire. There were 153 (74.6%) and 142 (69.3%) patients who met the MCID and PASS for the HOS-SSS, respectively, and 145 (70.7%) who met the PASS for iHOT-12. The proportion of patients who achieved the

TABLE 5
Intraoperative Procedures per Group^a

	Retroversion	Control	P Value
Labral treatment			.430
Debridement	22 (10.7)	18 (8.8)	
Reconstruction	2 (1)	5 (2.4)	
Repair	181 (88.3)	182 (88.8)	
Capsular treatment			.741
No repair	55 (26.8)	59 (28.8)	
Repair	150 (73.2)	146 (71.2)	
Acetabuloplasty	173 (84.4)	165 (80.5)	.364
Femoroplasty	136 (66.3)	164 (80)	.003

^aValues are presented as No. (%). Bold indicates statistical significance ($P < .05$).

MCID and PASS for these outcomes did not differ significantly from the control group.

Secondary Hip Preservation Surgery and Conversion to THA

At 5-year follow-up, 91.2% (95% CI, 87.3%-95.3%) of hips in the acetabular retroversion group and 88.9% (95% CI, 84.6%-93.4%) in the control group had not required any secondary hip procedures (Figure 3). At latest follow-up, 21 hips in the acetabular retroversion group and 22 in the control group required a secondary hip preservation procedure ($P = .86$). Of the 21 patients in the acetabular retroversion group, 1 required an open procedure to treat a femoral neck stress fracture, while the remaining 20 underwent secondary hip arthroscopy. Of the 22 patients in the control group, 2 required a secondary arthroscopy in addition to an open procedure for the removal of heterotopic ossification. Mean time to secondary hip preservation surgery for the acetabular retroversion and control groups was 31.7 ± 28.6 months and 22.2 ± 15.0 months, respectively ($P = .183$).

Of the patients who required a secondary hip preservation procedure, 17 in each group had minimum 1-year follow-up after their secondary procedure. The mean follow-up times were 56.4 ± 26.0 months and 54.9 ± 26.0 months for the acetabular retroversion and control groups, respectively ($P = .864$). At latest follow-up after the secondary procedure, the control group scored significantly higher for the SF-12 Physical (47.7 ± 7.9 vs 38.5 ± 9.9 ; $P = .006$) and VR-12 Physical (49.2 ± 7.7 vs 41.0 ± 10.3 ; $P = .020$). No other PROs yielded significant differences.

Regarding rates of conversion to THA, there was 100% survivorship in the study group and the control group at 5-year follow-up. At latest follow-up, 3 (1.5%) hips in the acetabular retroversion group and 2 (1.0%) in the control group required THA ($P = .54$). The mean time to conversion to THA was 72.2 ± 2.5 months and 99.2 ± 9.9 months for the acetabular retroversion and control groups, respectively.

TABLE 6
Radiographic Findings per Group^a

	Retroversion	Control	P Value
LCEA, deg			
Preoperative	30.16 ± 5.72 (29.37-30.95)	30.13 ± 5.95 (29.31-30.95)	.953
Postoperative	28.10 ± 5.64 (27.21-29.00)	29.14 ± 4.84 (28.38-29.90)	.132
P value	<.001	.037	
ACEA, deg			
Preoperative	32.77 ± 7.22 (31.65-33.90)	31.83 ± 7.47 (30.72-32.95)	.120
Postoperative	29.93 ± 7.75 (28.69-31.16)	30.63 ± 6.51 (29.60-31.66)	.389
P value	<.001	.178	
Acetabular inclination, deg			
Preoperative	3.51 ± 4.22 (2.85-4.17)	3.85 ± 4.14 (3.23-4.47)	.339
Postoperative	4.50 ± 4.20 (3.83-5.17)	3.88 ± 3.93 (3.26-4.51)	.143
P value	.025	.981	
Alpha angle, deg			
Preoperative	58.14 ± 11.34 (56.36-59.92)	61.25 ± 12.61 (59.36-63.14)	.028
Postoperative	44.57 ± 7.58 (43.36-45.79)	43.97 ± 7.27 (42.82-45.13)	.6
P value	<.001	<.001	

^aValues are presented as mean ± SD (95% CI). Bold indicates statistical significance ($P < .05$). ACEA, anterior center-edge angle; LCEA, lateral center-edge angle.

TABLE 7
Patient-Reported Outcomes per Group^a

	Retroversion	Control	P Value
mHHS			
Preoperative	65.08 ± 15.12 (63.00 to 67.16)	66.12 ± 14.38 (64.14 to 68.10)	.882
Latest	87.06 ± 14.22 (85.10 to 89.02)	86.86 ± 14.50 (84.87 to 88.86)	.855
P value	<.001	<.001	
Δ	22.04 ± 19.46 (19.36 to 24.72)	20.74 ± 19.27 (18.09 to 23.39)	.496
NAHS			
Preoperative	63.74 ± 16.99 (61.40 to 66.08)	64.71 ± 16.39 (62.45 to 66.96)	.720
Latest	85.80 ± 15.41 (83.67 to 87.93)	85.93 ± 14.53 (83.93 to 87.93)	.981
P value	<.001	<.001	
Δ	22.12 ± 20.05 (19.36 to 24.89)	21.23 ± 19.13 (18.59 to 23.86)	.643
HOS-SSS			
Preoperative	5.52 ± 2.23 (5.21 to 5.82)	5.44 ± 2.26 (5.13 to 5.75)	.685
Latest	76.15 ± 24.88 (72.50 to 79.80)	74.92 ± 24.71 (71.41 to 78.43)	.588
P value	<.001	<.001	
Δ	30.59 ± 31.31 (26.18 to 35.00)	27.01 ± 29.37 (22.87 to 31.14)	.244
VAS			
Preoperative	5.52 ± 2.23 (5.21 to 5.82)	5.44 ± 2.26 (5.13 to 5.75)	.685
Latest	1.89 ± 2.16 (1.57 to 2.20)	2.23 ± 2.26 (1.91 to 2.56)	.134
P value	<.001	<.001	
Δ	-3.54 ± 2.78 (-3.93 to -3.15)	-3.24 ± 2.93 (-3.65 to -2.83)	.234
iHOT-12	77.22 ± 23.26 (73.87 to 80.56)	76.50 ± 20.77 (73.60 to 79.41)	.409
SF-12			
Mental	56.15 ± 6.91 (55.13 to 57.16)	56.42 ± 7.70 (55.33 to 57.52)	.207
Physical	50.25 ± 8.31 (49.02 to 51.47)	50.13 ± 8.52 (48.91 to 51.34)	.709
VR-12			
Mental	61.03 ± 6.69 (60.05 to 62.02)	61.44 ± 7.13 (60.42 to 62.45)	.364
Physical	51.56 ± 7.78 (50.42 to 52.71)	51.68 ± 7.64 (50.59 to 52.77)	.788
Patient satisfaction	8.07 ± 2.39 (7.72 to 8.42)	8.28 ± 1.77 (8.02 to 8.53)	.341

^aValues are presented as mean ± SD (95% CI). Bold indicates statistical significance ($P < .05$). HOS-SSS, Hip Outcome Score—Sports Specific Scale; iHOT-12, International Hip Outcome Tool; mHHS, modified Harris Hip Score; NAHS, Non-arthritis Hip Score; SF-12, 12-Item Short Form Health Survey; VAS, visual analog scale; VR-12, Veterans RAND 12-Item Health Survey.

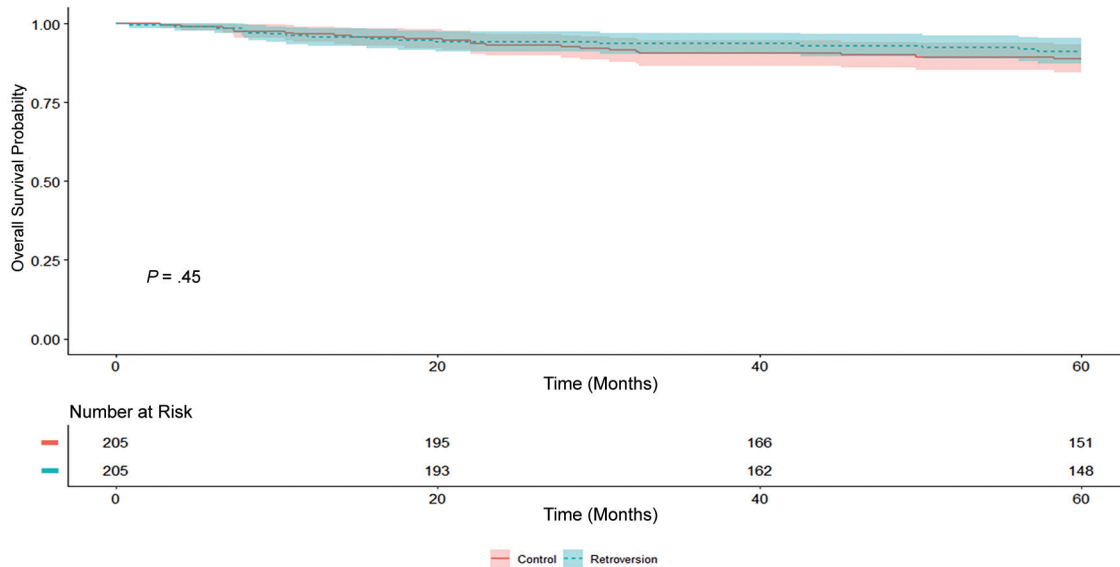


Figure 3. Kaplan-Meier survival curve with secondary hip preservation surgery as an endpoint. Shaded area spans the 95% CIs around the survival probabilities for each group.

TABLE 8
MCID and PASS per Group^a

	Hips, No. (%)		P Value
	Retroversion	Control	
mHHS			
MCID $\Delta \geq 8$	156 (76.1)	154 (75.1)	.476
PASS, ≥ 74	167 (81.5)	168 (82)	.602
HOS-SSS			
MCID $\Delta \geq 6$	153 (74.6)	159 (77.6)	.737
PASS, ≥ 65	142 (69.3)	136 (66.3)	.597
iHOT-12			
PASS, ≥ 63	145 (70.7)	150 (73.2)	.660
VAS			
MCID $\Delta \leq -1.5$	162 (79)	150 (73.2)	.203

^a Δ , change from pre- to postoperative; HOS-SSS, Hip Outcome Score—Sports Specific Scale; iHOT-12, International Hip Outcome Tool; MCID, minimal clinically important difference; mHHS, modified Harris Hip Score; PASS, patient acceptable symptomatic state; VAS, visual analog scale.

DISCUSSION

The present study reports the following findings: (1) patients who underwent isolated hip arthroscopy surgery for FAIS correction and labral tear treatment in the presence of acetabular retroversion experienced favorable results and significant improvement in several PROs at midterm follow-up; (2) as compared with a propensity-matched control without acetabular retroversion and similar baseline PROs, patients with acetabular retroversion reported comparable scores at midterm follow-up in regard to mHHS, NAHS, and HOS-SSS, in addition to VAS; (3) matched groups demonstrated similar midterm postoperative results for iHOT-12, SF-12 Mental and Physical, VR-12 Mental and

Physical, and, importantly, patient satisfaction; and (4) the proportion of patients in matched groups that reached the MCID/PASS for mHHS and HOS-SSS, the PASS for iHOT-12, and the MCID for VAS demonstrated no significant difference.

Vahedi et al⁷⁰ recently published their results on the treatment of FAIS and labral tears in patients with acetabular retroversion using a mini-open approach in a series of 51 patients. The authors compared outcomes between these patients and 550 without dysplasia or retroversion who also underwent FAIS treatment through a mini-open approach. At minimum 2-year follow-up, the study group reached significant postoperative improvement in mHHS. However, such improvement was significantly inferior to that of the control group. They concluded that FAIS in the context of acetabular retroversion may be treated by femoroplasty and acetabuloplasty with a mini-open approach, but the outcome appears to be inferior when compared with patients with FAIS and no evidence of dysplasia or acetabular retroversion. As presented, the current study reached different conclusions. In the study by Vahedi et al, the acetabular retroversion group was formed by 51 patients, and an a priori power analysis was not performed. Additionally, a comparison was made with a nonmatched group, and numerous confounding variables could be affecting those results. Patients with Tönnis grade 2 osteoarthritis were included in the study group (11.7%). Only 1 hip preservation design questionnaire was used (mHHS), which could compromise the generalizability of the results. Furthermore, MCID and PASS were not provided, which may make it difficult to distinguish a clinical difference between the groups. These limitations were overcome by the present study.

Flores et al²² presented their results for arthroscopic management of global acetabular retroversion, reporting and comparing PROs at 1 year postoperatively. In total, 39 patients with acetabular retroversion were matched

on the basis of sex, age, and BMI to 39 patients with focal pincer-type FAIS. Similar to the ongoing study, the authors reported significant improvement in mHHS, Hip Disability and Osteoarthritis Outcome Score (HOOS), 12-Item Short-Form Health Survey, and VAS for pain ($P < .001$) when comparing the results of the study group (acetabular retroversion) with the control group (focal pincer-type FAIS). Furthermore, no difference was found in the mean change of PROs between groups. Interestingly, subspine decompression in the acetabular retroversion group was associated with a significantly higher score for HOOS–Quality of Life and HOOS–Pain, although the reasons or clinical relevance behind this finding were not determined. Flores et al proposed that limited anterior acetabuloplasty is key to avoid iatrogenic instability, a concept with which we agree.²⁷ A greater decrease in LCEA after acetabuloplasty has been associated with failure of arthroscopic treatment of acetabular retroversion.⁵⁷ The current study supports the findings presented by Flores et al regarding arthroscopic management of FAIS and labral tears in the setting of global acetabular retroversion without frank dysplasia (LCEA $<18^\circ$), with the critical addition of longer follow-up and greater clinical relevance by providing the MCID and/or PASS for several PROs and VAS.

Poehling-Monaghan et al⁵⁷ reported that sex was a risk factor for failure of hip arthroscopy treatment for retroversion, with failure being defined as revision surgery, conversion to rPAO or THA, or mHHS <80 . After femoral osteoplasty and acetabular osteoplasty, male patients were more likely to have successful outcomes. In fact, 90% of male patients had successful outcomes versus only 40% of female patients ($P < .03$) with a mean follow-up of 30 months. Furthermore, survivorship among male versus female patients at 1 year (100% vs 68%) and 2 years (72% vs 44%) was also significantly different postoperatively ($P < .02$). In the current study, sex was a variable part of the propensity matching process, and no difference regarding sex distribution was obtained for the study and control groups. The rate of failure reported by Poehling-Monaghan et al was surprisingly high at 50%, a finding that led the authors to indicate “overall poor results for the arthroscopic treatment of patients with acetabular retroversion.” However, with a more representative number of patients, we obtained encouraging outcomes and significant improvement in midterm results that were similar to those of the control group, not only in terms of PROs, but in clinical significance.

In the absence of dysplasia, rPAO has traditionally been used for the treatment of global acetabular retroversion.^{65,72} In a recent systematic review, Litrenta et al³⁴ concluded that PRO improvement was observed with open and arthroscopic approaches.⁷⁰ The authors also stated that direct comparison between rPAO and hip arthroscopy was not possible owing to the heterogeneity of the studies. Nevertheless, longer follow-up was obtained for the open option. The results presented here add data to the current literature paucity in regard to midterm arthroscopic follow-up, although it is critical to point out that frank hip dysplasia was implemented as an exclusion criterion. Therefore, it cannot be extrapolated to the specific retroverted acetabula of patients with frank dysplasia.

Strengths

Several strengths are present in the current study. First, this is one of the few studies to investigate and report PROs for patients with arthroscopically managed acetabular retroversion and midterm follow-up. Second, propensity matching allows these results to be compared with those of a propensity-matched control group without acetabular retroversion in an effort to limit the effect of confounding variables. Third, through the use of several PROs that were designed to detect outcomes in active patients with nonarthritic hips, we tried to limit the ceiling effect of single-PRO use. Fourth, as mentioned by Harris et al,²⁵ statistically significant findings are not equal to meaningful or relevant clinical results. Accordingly, the PASS and/or MCID was calculated for the mHHS, HOS-SSS, and iHOT-12, in addition to the MCID for VAS, for better interpretation of the study's results.³⁵ Fifth, we performed an a priori power analysis, which identified that the sample size was sufficiently representative to establish meaningful differences between the study and control groups, increasing the generalizability of the results.

Limitations

The present study is not without limitations. Confounding variables may have influenced the findings and results, as this study was nonrandomized. No comparison was performed with other advocated surgical alternatives to treat acetabular retroversion, such as rPAO.^{53,70,73} Future research is necessary that compares, in a pair-match fashion, hip arthroscopy with rPAO in this population. Although this is a midterm follow-up study, longer follow-up is still needed to determine the durability of the results. The analysis of this study was based on patients from a single high-volume surgeon who specializes in hip preservation surgery, which may limit the generalizability of the results or lead to nonreproducible findings.⁴⁷ Furthermore, secondary hip preservation surgery was considered an endpoint outcome. In consequence, postoperative PROs for these patients were excluded from the matched-pair PRO analysis. However, the latest PROs of patients who required a secondary hip preservation procedure were compared between the groups. Surgical decision making, management, and treatment of labrum and capsule in hip arthroscopy have evolved and improved. Correspondingly, patients in the study and control groups who underwent labral debridement and capsulotomy without repair would be currently treated with labral restoration techniques, such as labral reconstruction/augmentation and capsular plication.^{17,19,38,51,56} The study design is retrospective, which may introduce bias. However, this may be limited by the prospective data collection. Hip dysplasia is a multiplex tridimensional structural pathology, and assessment based only on LCEA may be oversimplistic.³ Moreover, patients with borderline dysplasia, defined as LCEA between 19° and 25° , were not excluded from the present study, which may introduce heterogeneity in the patient cohort. Although this is

a propensity-matched control study, several variables (eg, generalized ligamentous laxity and femoral version) were not included into the matching design and may introduce potential confounding bias.^{7,62} Preoperative alpha angle and femoroplasty rate were statistically different between the groups, and the potential confounding effects cannot be elucidated by the present study. Finally, although the cut-off age value used (≤ 40 years) was based on previous research on this subject,²⁷ it is still arbitrary and may decrease the number of patients in the current investigation and consequently decrease the power of the study.

CONCLUSION

In the setting of FAIS and labral tears, patients with acetabular retroversion can be safely treated with advanced hip arthroscopic techniques without rPAO in a high-volume surgeon's hands. Patients with acetabular retroversion demonstrated favorable PROs at midterm follow-up. Furthermore, the improvement and proportion of patients reaching MCID and PASS for several PROs were comparable with those of a propensity-matched control group without acetabular retroversion.

REFERENCES

- Aprato A, Jayasekera N, Villar RN. Does the modified Harris Hip Score reflect patient satisfaction after hip arthroscopy? *Am J Sports Med.* 2012;40(11):2557-2560.
- Austin PC. Optimal caliper widths for propensity-score matching when estimating differences in means and differences in proportions in observational studies. *Pharm Stat.* 2011;10(2):150-161.
- Beaulé PE. Editorial commentary: quantifying anterior and lateral acetabular coverage in hip dysplasia. What about posterior coverage? *Arthroscopy.* 2019;35(4):1117-1119.
- Botser IB, Martin DE, Stout CE, Domb BG. Tears of the ligamentum teres: prevalence in hip arthroscopy using 2 classification systems. *Am J Sports Med.* 2011;39(1)(suppl):117-125.
- Briggs KK, Bolia IK. Hip arthroscopy: an evidence-based approach. *Lancet.* 2018;391(10136):2189-2190.
- Chahal J, Van Thiel GS, Mather RC, et al. The patient acceptable symptomatic state for the modified Harris Hip Score and Hip Outcome Score among patients undergoing surgical treatment for femoroacetabular impingement. *Am J Sports Med.* 2015;43(8):1844-1849.
- Chaharbakshi EO, Hartigan DE, Perets I, Domb BG. Is hip arthroscopy effective in patients with combined excessive femoral anteversion and borderline dysplasia? A match-controlled study. *Am J Sports Med.* 2019;47(1):123-130.
- Chandrasekaran S, Darwish N, Mu BH, et al. Arthroscopic reconstruction of the irreparable acetabular labrum: a match-controlled study. *Arthroscopy.* 2019;35(2):480-488.
- Chandrasekaran S, Gui C, Walsh JP, Lodhia P, Suarez-Ahedo C, Domb BG. Correlation between changes in visual analog scale and patient-reported outcome scores and patient satisfaction after hip arthroscopic surgery. *Orthop J Sports Med.* 2017;5(9):2325967117724772.
- Chandrasekaran S, Vemula SP, Martin TJ, Suarez-Ahedo C, Lodhia P, Domb BG. Arthroscopic technique of capsular plication for the treatment of hip instability. *Arthrosc Tech.* 2015;4(2):e163-e167.
- Chen AW, Yuen LC, Ortiz-Declet V, Litrenta J, Maldonado DR, Domb BG. Selective debridement with labral preservation using narrow indications in the hip: minimum 5-year outcomes with a matched-pair labral repair control group. *Am J Sports Med.* 2018;46(2):297-304.
- Christensen CP, Althausen PL, Mittleman MA, Lee J, McCarthy JC. The nonarthritic hip score: reliable and validated. *Clin Orthop Relat Res.* 2003;406:75-83.
- Clohisey JC, Carlisle JC, Beaulé PE, et al. A systematic approach to the plain radiographic evaluation of the young adult hip. *J Bone Joint Surg Am.* 2008;90(suppl 4):47-66.
- Clohisey JC, Knaus ER, Hunt DM, Leshner JM, Harris-Hayes M, Prather H. Clinical presentation of patients with symptomatic anterior hip impingement. *Clin Orthop Relat Res.* 2009;467(3):638-644.
- Colvin AC, Koehler SM, Bird J. Can the change in center-edge angle during pincer trimming be reliably predicted? *Clin Orthop Relat Res.* 2011;469(4):1071-1074.
- Domb B, Hanypsiak B, Botser I. Labral penetration rate in a consecutive series of 300 hip arthroscopies. *Am J Sports Med.* 2012;40(4):864-869.
- Domb BG, Battaglia MR, Perets I, et al. Minimum 5-year outcomes of arthroscopic hip labral reconstruction with nested matched-pair benchmarking against a labral repair control group. *Am J Sports Med.* 2019;47(9):2045-2055.
- Domb BG, Chaharbakshi EO, Rybalko D, Close MR, Litrenta J, Perets I. Outcomes of hip arthroscopic surgery in patients with Tönnis grade 1 osteoarthritis at a minimum 5-year follow-up: a matched-pair comparison with a Tönnis grade 0 control group. *Am J Sports Med.* 2017;45(10):2294-2302.
- Domb BG, Hartigan DE, Perets I. Decision making for labral treatment in the hip: repair versus debridement versus reconstruction. *J Am Acad Orthop Surg.* 2017;25(3):e53-e62.
- Domb BG, Martin TJ, Gui C, Chandrasekaran S, Suarez-Ahedo C, Lodhia P. Predictors of clinical outcomes after hip arthroscopy: a prospective analysis of 1038 patients with 2-year follow-up. *Am J Sports Med.* 2018;46(6):1324-1330.
- Dunn DM. Anteversion of the neck of the femur; a method of measurement. *J Bone Joint Surg Br.* 1952;34(2):181-186.
- Flores SE, Chambers CC, Borak KR, Zhang AL. Arthroscopic treatment of acetabular retroversion with acetabuloplasty and subspine decompression: a matched comparison with patients undergoing arthroscopic treatment for focal pincer-type femoroacetabular impingement. *Orthop J Sports Med.* 2018;6(7):2325967118783741.
- Gray AJ, Villar RN. The ligamentum teres of the hip: an arthroscopic classification of its pathology. *Arthroscopy.* 1997;13(5):575-578.
- Griffin DR, Dickenson EJ, Wall PDH, et al. Hip arthroscopy versus best conservative care for the treatment of femoroacetabular impingement syndrome (UK FASHIoN): a multicentre randomised controlled trial. *Lancet.* 2018;391(10136):2225-2235.
- Harris JD, Brand JC, Cote MP, Faucett SC, Dhawan A. Research pearls: the significance of statistics and perils of pooling. Part 1: clinical versus statistical significance. *Arthroscopy.* 2017;33(6):1102-1112.
- Harris MD, Kapron AL, Peters CL, Anderson AE. Correlations between the alpha angle and femoral head asphericity: implications and recommendations for the diagnosis of cam femoroacetabular impingement. *Eur J Radiol.* 2014;83(5):788-796.
- Hartigan DE, Perets I, Walsh JP, Close MR, Domb BG. Clinical outcomes of hip arthroscopy in radiographically diagnosed retroverted acetabula. *Am J Sports Med.* 2016;44(10):2531-2536.
- Inacio MCS, Chen Y, Paxton EW, Namba RS, Kurtz SM, Cafri G. Statistics in brief: an introduction to the use of propensity scores. *Clin Orthop Relat Res.* 2015;473(8):2722-2726.
- Jackson TJ, Hammarstedt JE, Vemula SP, Domb BG. Acetabular labral base repair versus circumferential suture repair: a matched-pair comparison of clinical outcomes. *Arthroscopy.* 2015;31(9):1716-1721.
- Jamali AA, Mladenov K, Meyer DC, et al. Anteroposterior pelvic radiographs to assess acetabular retroversion: high validity of the "cross-over-sign." *J Orthop Res.* 2007;25(6):758-765.
- Kalberer F, Sierra RJ, Madan SS, Ganz R, Leunig M. Ischial spine projection into the pelvis: a new sign for acetabular retroversion. *Clin Orthop Relat Res.* 2008;466(3):677-683.
- Lall AC, Saadat AA, Battaglia MR, Maldonado DR, Perets I, Domb BG. Perineal pressure during hip arthroscopy is reduced by use of

- Trendelenburg: a prospective study with randomized order of positioning. *Clin Orthop Relat Res.* 2019;477(8):1851-1857.
33. Lequesne M, de SEZE null. False profile of the pelvis: a new radiographic incidence for the study of the hip. Its use in dysplasias and different coxopathies [in French]. *Rev Rhum Mal Osteoartic.* 1961;28:643-652.
 34. Litrenta J, Mu B, Chen AW, Ortiz-Declet V, Perets I, Domb BG. Radiographic and clinical outcomes of adolescents with acetabular retroversion treated arthroscopically. *J Pediatr Orthop.* 2019;39(10):510-515.
 35. Lubowitz JH, Brand JC, Rossi MJ. Our measure of medical research should be appreciable benefit to the patient. *Arthroscopy.* 2019;35(7):1943-1944.
 36. Maldonado DR, Chen JW, Walker-Santiago R, et al. Forget the greater trochanter! Hip joint access with the 12 o'clock portal in hip arthroscopy. *Arthrosc Tech.* 2019;8(6):e575-e584.
 37. Maldonado DR, Lall AC, Battaglia MR, Laseter JR, Chen JW, Domb BG. Arthroscopic iliopsoas fractional lengthening. *JBJS Essent Surg Tech.* 2018;8(4):e30.
 38. Maldonado DR, Lall AC, Walker-Santiago R, et al. Hip labral reconstruction: consensus study on indications, graft type and technique among high-volume surgeons. *J Hip Preserv Surg.* 2019;6(1):41-49.
 39. Maldonado DR, LaReau JM, Perets I, et al. Outcomes of hip arthroscopy with concomitant periacetabular osteotomy, minimum 5-year follow-up. *Arthroscopy.* 2019;35(3):826-834.
 40. Maldonado DR, Laseter JR, Perets I, et al. The effect of complete tearing of the ligamentum teres in patients undergoing primary hip arthroscopy for femoroacetabular impingement and labral tears: a match-controlled study. *Arthroscopy.* 2019;35(1):80-88.
 41. Mansor Y, Perets I, Close MR, Mu BH, Domb BG. In search of the spherical femoroplasty: cam overresection leads to inferior functional scores before and after revision hip arthroscopic surgery. *Am J Sports Med.* 2018;46(9):2061-2071.
 42. Martin HD. Clinical examination of the hip. *Oper Tech Orthop.* 2005;15(3):177-181.
 43. Martin RL, Kivlan BR, Christoforetti JJ, et al. Minimal clinically important difference and substantial clinical benefit values for a pain visual analog scale after hip arthroscopy. *Arthroscopy.* 2019;35(7):2064-2069.
 44. Martin RL, Philippon MJ. Evidence of validity for the hip outcome score in hip arthroscopy. *Arthroscopy.* 2007;23(8):822-826.
 45. McCarthy J, Noble P, Aluisio FV, Schuck M, Wright J, Lee J. Anatomy, pathologic features, and treatment of acetabular labral tears. *Clin Orthop Relat Res.* 2003;406:38-47.
 46. McClincy MP, Wylie JD, Kim Y-J, Millis MB, Novais EN. Periacetabular osteotomy improves pain and function in patients with lateral center-edge angle between 18° and 25°, but are these hips really borderline dysplastic? *Clin Orthop Relat Res.* 2019;477(5):1145-1153.
 47. Mehta N, Chamberlin P, Marx RG, et al. Defining the learning curve for hip arthroscopy: a threshold analysis of the volume-outcomes relationship. *Am J Sports Med.* 2018;46(6):1284-1293.
 48. Meyer DC, Beck M, Ellis T, Ganz R, Leunig M. Comparison of six radiographic projections to assess femoral head/neck asphericity. *Clin Orthop Relat Res.* 2006;445:181-185.
 49. Nwachukwu BU, Chang B, Beck EC, et al. How should we define clinically significant outcome improvement on the iHOT-12? *HSS J.* 2019;15(2):103-108.
 50. Ortiz-Declet V, Mu B, Chen AW, et al. The "bird's eye" and "upper deck" views in hip arthroscopy: powerful arthroscopic perspectives for acetabuloplasty. *Arthrosc Tech.* 2018;7(1):e13-e16.
 51. Ortiz-Declet V, Mu B, Chen AW, et al. Should the capsule be repaired or plicated after hip arthroscopy for labral tears associated with femoroacetabular impingement or instability? A systematic review. *Arthroscopy.* 2018;34(1):303-318.
 52. Outerbridge RE. The etiology of chondromalacia patellae. *J Bone Joint Surg Br.* 1961;43:752-757.
 53. Parry JA, Swann RP, Erickson JA, Peters CL, Trousdale RT, Sierra RJ. Midterm outcomes of reverse (anteverting) periacetabular osteotomy in patients with hip impingement secondary to acetabular retroversion. *Am J Sports Med.* 2016;44(3):672-676.
 54. Perets I, Rybalko D, Chaharbakshi EO, Mu BH, Chen AW, Domb BG. Minimum five-year outcomes of hip arthroscopy for the treatment of femoroacetabular impingement and labral tears in patients with obesity: a match-controlled study. *J Bone Joint Surg Am.* 2018;100(11):965-973.
 55. Peters CL, Anderson LA, Erickson JA, Anderson AE, Weiss JA. An algorithmic approach to surgical decision making in acetabular retroversion. *Orthopedics.* 2011;34(1):10.
 56. Philippon MJ, Bolia IK, Locks R, Briggs KK. Labral preservation: outcomes following labrum augmentation versus labrum reconstruction. *Arthroscopy.* 2018;34(9):2604-2611.
 57. Poehling-Monaghan KL, Krych AJ, Levy BA, Trousdale RT, Sierra RJ. Female sex is a risk factor for failure of hip arthroscopy performed for acetabular retroversion. *Orthop J Sports Med.* 2017;5(11):232596711773747.
 58. Redmond JM, Cregar WM, Martin TJ, Vemula SP, Gupta A, Domb BG. Arthroscopic labral reconstruction of the hip using semitendinosus allograft. *Arthrosc Tech.* 2015;4(4):e323-e329.
 59. Redmond JM, El Bitar YF, Gupta A, Stake CE, Vemula SP, Domb BG. Arthroscopic acetabuloplasty and labral refixation without labral detachment. *Am J Sports Med.* 2015;43(1):105-112.
 60. Redmond JM, Gupta A, Hammarstedt JE, Stake CE, Dunne KF, Domb BG. Labral injury: radiographic predictors at the time of hip arthroscopy. *Arthroscopy.* 2015;31(1):51-56.
 61. Redmond JM, Gupta A, Stake CE, Domb BG. The prevalence of hip labral and chondral lesions identified by method of detection during periacetabular osteotomy: arthroscopy versus arthrotomy. *Arthroscopy.* 2014;30(3):382-388.
 62. Saadat AA, Lall AC, Battaglia MR, Mohr MR, Maldonado DR, Domb BG. Prevalence of generalized ligamentous laxity in patients undergoing hip arthroscopy: a prospective study of patients' clinical presentation, physical examination, intraoperative findings, and surgical procedures. *Am J Sports Med.* 2019;47(4):885-893.
 63. Seldes RM, Tan V, Hunt J, Katz M, Winiarsky R, Fitzgerald RH. Anatomy, histologic features, and vascularity of the adult acetabular labrum. *Clin Orthop Relat Res.* 2001;382:232-240.
 64. Siebenrock KA, Schaller C, Tannast M, Keel M, Buechler L. Anteverting periacetabular osteotomy for symptomatic acetabular retroversion: results at ten years. *J Bone Joint Surg Am.* 2014;96(21):1785-1792.
 65. Siebenrock KA, Schoeniger R, Ganz R. Anterior femoro-acetabular impingement due to acetabular retroversion: treatment with periacetabular osteotomy. *J Bone Joint Surg Am.* 2003;85(2):278-286.
 66. Siebenrock KA, Steppacher SD, Tannast M, Buechler L. Anteverting periacetabular osteotomy for acetabular retroversion. *JBJS Essent Surg Tech.* 2015;5(1):e1.
 67. Sierra RJ. CORR Insights®: periacetabular osteotomy provides higher survivorship than rim trimming for acetabular retroversion. *Clin Orthop Relat Res.* 2017;475(4):1151-1153.
 68. Sierra RJ. The management of acetabular retroversion with reverse periacetabular osteotomy. *Instr Course Lect.* 2013;62:305-313.
 69. Tönnis D, Heinecke A. Acetabular and femoral anteversion: relationship with osteoarthritis of the hip. *J Bone Joint Surg Am.* 1999;81(12):1747-1770.
 70. Vahedi H, Aalirezaie A, Schlitt PK, Parvizi J. Acetabular retroversion is a risk factor for less optimal outcome after femoroacetabular impingement surgery. *J Arthroplasty.* 2019;34(7):1342-1346.
 71. Walker-Santiago R, Ortiz-Declet V, Maldonado DR, Wojnowski NM, Domb BG. The modified resisted internal rotation test for detection of gluteal tendon tears. *Arthrosc Tech.* 2019;8(3):e331-e334.
 72. Wyatt MC, Smith C, Zavareh A, Pfluger D, Bankes MJ. Functional acetabular retroversion syndrome: description of a specific sub-type of FAI and results of treatment with minimally invasive PAO [published online June 9, 2019]. *Hip Int.* doi:10.1177/1120700019855240
 73. Zurmuhle CA, Anwander H, Albers CE, et al. Periacetabular osteotomy provides higher survivorship than rim trimming for acetabular retroversion. *Clin Orthop Relat Res.* 2017;475(4):1138-1150.